

Transfusion-related acute lung injury (TRALI) after pediatric cardiac surgery: A case report

José Colleti Junior ^{1*}, Felipe Rezende Caino ¹, Werther Brunow de Carvalho ²

¹ Pediatric ICU, Hospital Santa Catarina, São Paulo, Brazil ² Children's Institute, Department of Pediatrics, University of São Paulo, São Paulo, Brazil

Abstract

Transfusion-related acute lung injury (TRALI), acute respiratory distress with noncardiogenic pulmonary edema that occurs within six hours of transfusion, is the leading cause of transfusion-related deaths. However, there is no reliable literature regarding the incidence of TRALI in the pediatric population. We report a case study of a 3-year-old boy presenting with TRALI syndrome four hours after heart surgery for atrial septal defect (ASD) closure for which he received the transfusion of red blood cells and fresh frozen plasma. We report this case with the aim that doctors become aware of the signs of TRALI to enable early intervention and the development of preventive measures.

Citation: Colleti Junior J, FRezende Caino F, Brunow de Carvalho W (2017) Transfusion-related acute lung injury (TRALI) after pediatric cardiac surgery: A case report. *Adv Pediatr Res* 4:1. doi:10.12715/apr.2017.4.1

Received: September 26, 2016; **Accepted:** December 15, 2017; **Published:** January 1, 2017

Copyright: © 2017 Colleti et al. This is an open access article distributed under the terms of the Creative Commons Attribution License, which permits unrestricted use, distribution, and reproduction in any medium, provided the original work is properly cited.

Competing interests: The authors have declared that no competing interests exist.

* Email: colleti@gmail.com

Introduction

Transfusion-related acute lung injury (TRALI) is an uncommon but potentially fatal transfusion reaction that is currently the leading cause of transfusion-related deaths [1]. Despite increased recognition, this complication continues to be significantly under recognized and underreported [1]. The diagnosis of TRALI is predominantly clinical and has been defined as acute respiratory distress with noncardiogenic pulmonary edema that occurs within six hours of transfusion [2]. There is no reliable literature regarding the incidence of TRALI in the pediatric population. One large study demonstrated that TRALI is relatively common in critically ill children, affecting 6.9% of transfused children [3], with an overall mortality of 16%. Hence, awareness of the syndrome and proper medical management are crucial for patients presenting with TRALI symptoms.

This case study reports a patient presenting with TRALI syndrome after heart surgery for atrial septal defect (ASD) closure.

Case report

A 3-year-old Brazilian boy, 13.1 kg, presenting with congenital ostium secundum ASD, was admitted to the hospital for surgery correction. The ASD was closed by suture and no problems were reported during the surgery. The patient was transfused with 300 mL of red blood cells in addition to 300 mL of fresh frozen plasma during the procedure. After surgery, the patient remained in the pediatric intensive care unit (ICU) with a persistent cardiac murmur. Echocardiography showed the persistence of the ASD, and the patient underwent a second surgery 20 days after the initial intervention. ASD closure was performed and 600 mL of red blood cells plus 150 mL of fresh frozen plasma was transfused.

Within four hours of surgery, the patient's condition rapidly deteriorated with symptoms of acute respiratory distress (tachypnea, dyspnea) and the development of hypoxemia and bradycardia. He received a bolus of intravenous epinephrine (0.1 mg/kg), along with calcium gluconate (1 mEq/kg), sodium bicarbonate (1 mEq/kg), and chest compressions for less than two minutes. The patient remained hemodynamically unstable with a low mean arterial pressure (35 mmHg), requiring a continuous infusion of epinephrine that was titrated to 1 mcg/kg/min. The patient remained intubated for mechanical ventilation, receiving sedation and analgesia with midazolam (0.2 mcg/kg/min) and fentanyl (2 mcg/kg/min), and was moved into the prone position. He remained on mechanical ventilation in pressure control mode (fraction of inspired oxygen, FiO_2 : 0.8; positive end-expiratory pressure, PEEP: 14 mmHg; breath-pressure-controlled, PC: 30 mmHg; respiratory rate, RR: 24 incursions per minute, ipm; inspiration time, T_{insp} : 0.65). Arterial gasometry showed pH: 7.13, oxygen tension, PaO_2 : 117; carbon dioxide tension, $PaCO_2$: 95; bicarbonate concentration, HCO_3 : 31.6; base excess, BE: +2.4, and oxyhemoglobin saturation, $SatO_2$: 97%. The calculated PaO_2/FiO_2 ratio was 146.2, indicating moderate acute respiratory distress syndrome (ARDS) according to the Berlin definition [4]. Milrinone (0.5 mcg/kg/min) and norepinephrine were associated to epinephrine to improve the hemodynamic status, and chest radiography revealed an interstitial bilateral infiltrate (Figure 1). The hypothesis of TRALI was suggested since there was a temporal relationship between the transfusion and the clinical features and the laboratory tests met all of the TRALI criteria.

After 12 hours in the prone position, arterial gasometry showed: pH: 7.36, $PaCO_2$: 49 mmHg, PaO_2 : 82 mmHg, HCO_3 : 31.9, BE: +4.7, and $SatO_2$: 93%. The mechanical ventilation settings were: FiO_2 : 0.40, PEEP: 8 mmHg, PC: 24 mmHg, RR: 24 ipm, and T_{insp} : 0.65. The calculated PaO_2/FiO_2 ratio rose to 205. On the second day after surgery, the vasoactive drugs were titrated down, the patient's condition improved, and we started weaning the mechanical ventilation. Chest radiography showed no remaining interstitial infiltrates (Figure 2) and the patient was extubated on the third day after surgery.

Echocardiography showed a good surgery result and the patient was discharged to the ward on the sixth day after surgery.

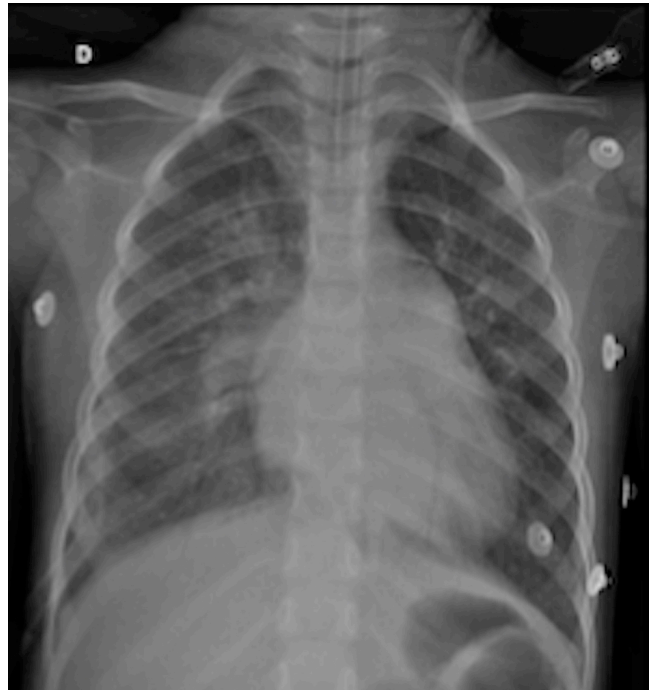


Figure 1. Chest radiograph 5 hours after surgery showing the interstitial bilateral infiltrates

Discussion

TRALI is a rare but dangerous complication of transfusion [3]. Although it usually develops in the perioperative period, it may develop under close hemodynamic monitoring during cardiac surgery. Little is known about the occurrence of TRALI in pediatric patients undergoing cardiac surgery. In previous retrospective studies, cardiac surgery was shown to be a risk factor for the onset of TRALI [5]. Aside from possible priming factors, these patients often receive transfusions of blood products.

The pathophysiology of TRALI is not completely understood. Proposed pathophysiologic mechanisms relate to the transfusion of blood components from blood donors whose plasma contains white blood cell antibodies, most commonly human leukocyte antibody (HLA) Class I and II antibodies, into

recipients with primed neutrophils due to an underlying disease. A second proposed mechanism relates to the transfusion of bioactive factors that activate primed neutrophils in the lungs causing direct pulmonary endothelial damage, capillary leak, and acute lung injury [6].

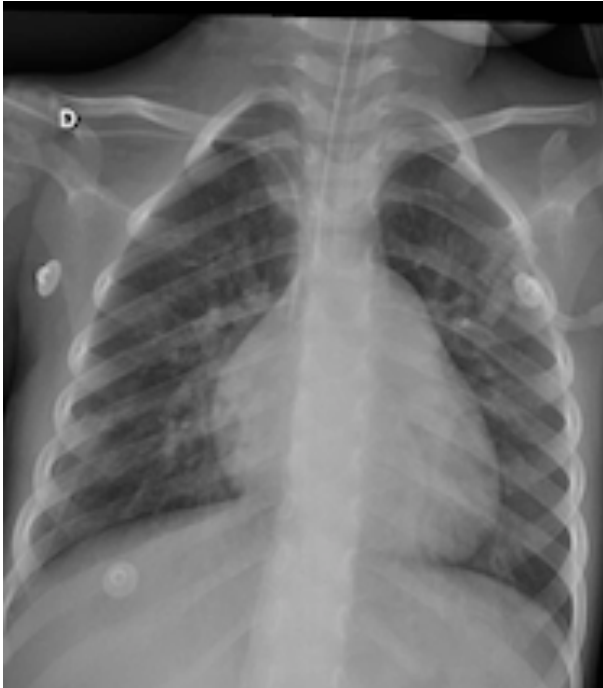

Figure 2. Chest radiograph 48 hours after surgery when the patient had improved

A two-hit hypothesis has been proposed for TRALI [7]. The first hit is caused by underlying patient factors, resulting in the adherence of primed neutrophils to the pulmonary endothelium. The second hit is caused by mediators in the blood transfusion that activate the endothelial cells and pulmonary neutrophils, resulting in capillary leakage and subsequent pulmonary edema. The second hit can be antibody-mediated or non-antibody-mediated. Recently, some studies suggest that TRALI is, in fact, multifactorial in nature [8].

The diagnosis of TRALI has been mainly clinical since the Canadian consensus conference in 2004 [2]. Clinical findings consist of the rapid onset of tachypnea, cyanosis, dyspnea, and fever (1° C or higher.). Although hypotension was reported in most

patients in the early clinical studies of TRALI, it is not a consistent finding. Auscultation of the lungs reveals diffuse crackles and decreased breath sounds, especially in dependent areas. Physiologic findings include acute hypoxemia, with $\text{PaO}_2/\text{FiO}_2$ less than 300 mmHg, and decreased pulmonary compliance despite normal cardiac function. Radiographic examination reveals diffuse, fluffy infiltrates consistent with pulmonary edema. In the present case, the patient fulfilled all criteria for a diagnosis of TRALI.

The differential diagnosis could include the following clinical syndromes: transfusion-associated circulatory overload (TACO), edema of another origin, anaphylactic transfusion reaction, transfusion reaction due to bacterial contamination, or a hemolytic reaction due to ABO group incompatibility.

Prevention of TRALI is based on all measures that aim to reduce the presence of HLA class I and II antibodies and human neutrophil antigen (HNA) antibodies in blood components [9]. These measures include appropriate donor selection for plasma donation, increasing the effectiveness of hemovigilance systems, performing techniques intended to reduce plasma volume in cellular blood components, and employing a restrictive transfusion strategy.

Transfusion does not appear to be a potent immunizing event [10]. Moreover, the low prevalence of previous transfusions in the donor population indicates that exclusion of these individuals would have minimal impact on the supply of high plasma volume components. However, in the case reported, the patient received blood products 20 days before the second surgery, when the TRALI syndrome appeared. Did this patient have immune response activation?

Conclusions

The incidence of TRALI due to blood product transfusions after cardiac surgery is reported to be 2.4% [11] and is associated with a high mortality rate if unrecognized. Doctors must become aware of the signs in order to enable early intervention, and the development of preventive measures could certainly contribute to a reduction in the incidence of TRALI.

References

1. Shaz BH, Stowell SR, Hillyer CD. Transfusion-related acute lung injury: from bedside to bench and back. *Blood* 2011;117:1463-71.
2. Kleinman S, Caulfield T, Chan P, Davenport R, McFarland J, McPhedran S, et al. Toward an understanding of transfusion-related acute lung injury: statement of a consensus panel. *Transfusion* 2004;44:1774-89.
3. Mulder HD, Augustijn QJ, van Woensel JB, Bos AP, Juffermans NP, Wösten-van Asperen RM. Incidence, risk factors, and outcome of transfusion-related acute lung injury in critically ill children: a retrospective study. *J Crit Care* 2015;30(1):55-9.
4. ARDS Definition Task Force, Ranieri VM, Rubenfeld GD, Thompson BT, Ferguson ND, Caldwell E, et al. Acute respiratory distress syndrome: the Berlin Definition. *JAMA*. 2012;307(23):2526-33.
5. Vlaar AP, Binnekade JM, Prins D, van Stein D, Hofstra JJ, Schultz MJ, et al. Risk factors and outcome of transfusion-related acute lung injury in the critically ill: a nested case control study. *Crit Care Med*. 2010;38(3):771-8.
6. El Kenz H, Van der Linden P. Transfusion-related acute lung injury. *Eur J Anaesthesiol*. 2014;31(7):345-50.
7. Vlaar AP, Juffermans NP. Transfusion-related acute lung injury: a clinical review. *Lancet* 2013;382(9896):984-94.
8. Middelburg RA, van der Bom JG. Transfusion-related acute lung injury not a two-hit, but a multicausal model. *Transfusion* 2015;55(5):953-60.
9. Müller MC, van Stein D, Binnekade JM, van Rhenen DJ, Vlaar AP. Low-risk transfusion-related acute lung injury donor strategies and the impact on the onset of transfusion-related acute lung injury: a meta-analysis. *Transfusion* 2015;55(1):164-75.
10. Toy P, Bacchetti P, Grimes B, Gajic O, Murphy EL, Winters JL, et al. Recipient clinical risk factors predominate in possible transfusion-related acute lung injury. *Transfusion* 2015;55(5):947-52.
11. Vlaar AP, Hofstra JJ, Determann RM, Veelo DP, Paulus F, Kulik W, et al. The incidence, risk factors, and outcome of transfusion-related acute lung injury in a cohort of cardiac surgery patients: a prospective nested case-control study. *Blood* 2011;117(16):4218-25.