

## SURGICAL ORTHODONTIC TREATMENT OF SEVERE SKELETAL CLASS II WITH VERTICAL MAXILLARY EXCESS

<sup>1</sup> Vivek Reddy Ganugapanta <sup>2</sup> Venkata Naidu Bavikati <sup>3</sup> Imran khan <sup>4</sup> Gowri sankar Singaraju	<sup>1</sup> Senior lecturer <sup>2</sup> Post graduate <sup>3</sup> Post graduate <sup>4</sup> Professor
---	--

<sup>1-4</sup> Department of Orthodontics, Narayana Dental College, Nellore, Andhra Pradesh, India.

**ABSTRACT:** This paper describes an adult male patient who presented with a severe skeletal class II deformity with severe gummy smile. The case was managed with a combination of presurgical orthodontic treatment followed by a double jaw orthognathic surgery and then another phase of orthodontic treatment for final occlusal detailing. Extraction of the upper fives and lower first premolars was done during the presurgical orthodontic phase of treatment to decompensate upper and lower incisors and to give room for surgical setback of the maxillary anterior segment. Double jaw surgery was performed: bilateral sagittal split ramus osteotomy (BSSO) for 6mm mandibular advancement combined with Le Fort I maxillary osteotomy with 8mm impaction of the maxilla. Although the anteroposterior discrepancy and the facial convexity were so severe, highly acceptable results were obtained, both esthetically as well as occlusally.

**KEYWORDS:** Orthognathic surgery ,

### INTRODUCTION

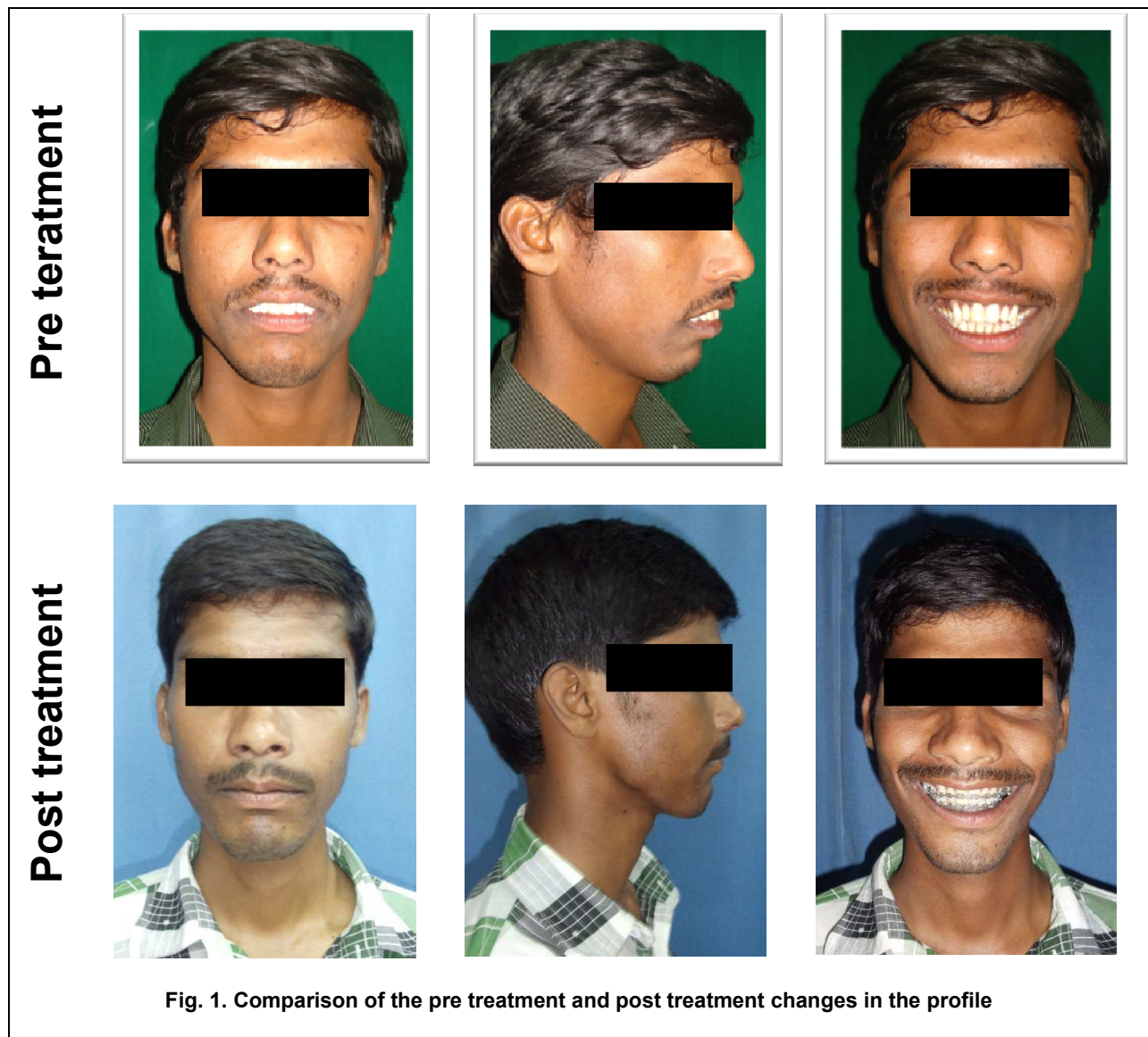Orthognathic surgery is considered for the treatment of dentofacialskeletal deformities for more than 100 years. Interestingly, the first jaw deformity correction was performed without anesthesia in the United States by Simon Hüllihen, an American general surgeon, in the mid of the 19<sup>th</sup> century. Dentofacialskeletal deformities always cause severe functional and esthetic problems to the patient. In adult severe cases, the combined approach, orthodontic and orthognathic surgery, is always the treatment of choice, and the results obtained usually ensure a better esthetic, functional, and stable results. Class II skeletal deformity is characterized by an exaggerated sagittal distance between the maxilla and the mandible, which could be the result of maxillary prognathism, mandibular retrognathism, or both. Presurgical orthodontic decompensation is essential to enable the surgeon to make a considerable amount of surgical correction, otherwise the esthetic and functional outcome of the entire procedure will not be that ideal<sup>1,2,3</sup>.

### Case Report

A 20-year-old male was referred to the orthodontic department for the treatment of "Bothering anterior teeth." At the first consultation visit, the patient expressed his great concerns about his anterior teeth in addition to his severely retruded chin.

The clinical examination of the patient revealed a severe skeletal class II pattern with a severe mandibular retrognathism. The frontal facial view showed a dolichofacial pattern, an excessive lower face height, and

an interlabial gap of 18 mm. The lips were incompetent at rest with the lower lip resting behind the upper incisors. At rest, there is a 10mm incisal show in addition to 4mm of the gum. The lips are incompetent at rest with a short upper lip, while the lower lip is resting behind the upper incisors. Upon smiling, there was a severe gingival show around 8 mm. The lateral view of the face revealed an average nose, a normal nasolabial angle, a convex profile, severe mandibular retrognathism, a severely deficient chin. Intraoral photographs reveal an end on molar and canine relation on both sides. The upper arch is V shaped, while the lower arch is U shaped. There is an excessive overjet, almost 12mm. Radiographically, the panoramic view revealed a normal bony trabeculation, the full number of permanent teeth. Cephalometric analysis revealed that the patient had a severe skeletal class II, and the ANB angle was 6° which is more resorted to the lower jaw. Upper incisor position was proclined and protruded, while the lower incisors were more severely proclined and protruded. Vertically, the patient had an increased lower face height. The chin was markedly deficient. After a complete diagnosis of the case, the patient was informed the detailed treatment plan, and it was explained to the patient that the presurgical orthodontic preparation "decompensation" of the dentition will worsen the deformity and that the malocclusion, facial profile, and speech will be temporarily worsened. The patient was further informed that this presurgical treatment only improves the bony support for the teeth, and all the facial and profile changes will result after the upcoming surgical procedures.



**Diagnosis**

**Treatment Objectives:** The treatment objectives were to improve the patient’s facial esthetics: patient’s facial profile, mandibular retrognathism, increased lower third of the face, gummy smile, incompetent lips, dental midline shift, and normalizing the overbite and overjet.

**Treatment Plan:** Presurgical orthodontic phase aimed to decompensate upper and lower incisors via extraction of the four first premolars. Anchorage was maximized in the upper arch through the use of transpalatal arch (TPA) in addition to including the upper second molars.

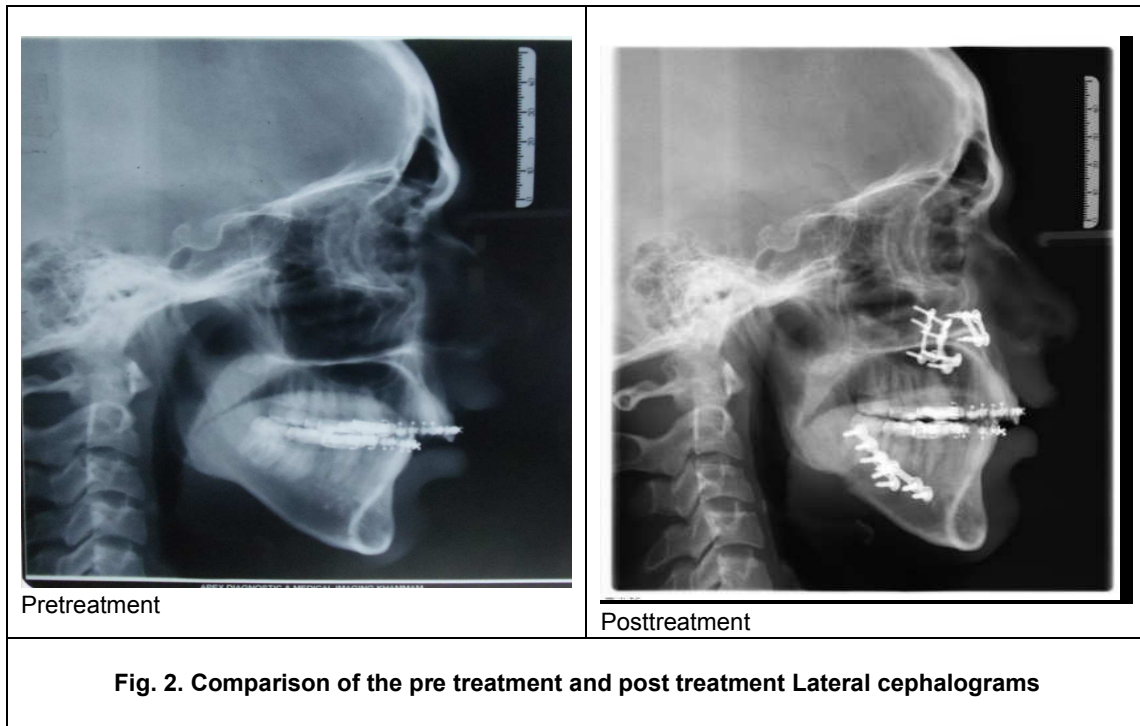
**Treatment Progress**

**Presurgical Orthodontic Treatment:** .Our aims from the presurgical treatment were to decompensate the upper and lower incisors and to level and align both arches and

relief of crowding in the lower arch. Upper second premolars and lower first premolars were extracted to get space for retracting the lower incisors, alleviation of lower arch crowding, uprighting the upper incisors. The patient received 0.022-inch MBT edgewise appliance. Initial leveling was accomplished with 0.016-inch nickel-titanium (Ni-Ti) arch wires. After initial leveling and alignment, the upper and lower cuspids were retracted; lower incisors were decompensated, and a space left in the upper premolars area for anterior maxillary was set back.

**Orthognathic Surgery**

**Preoperative Surgical Planning:**Upper and lower impressions were taken, and study casts were prepared. The models were mounted on a semi-adjustable articulator using a face-bow transfer. A full orthognathic model surgery was performed. Final and intermediate splints were fabricated using orthodontic cold-cure resin.



**Surgery.** A standard bilateral sagittal split incision was performed, and the medial aspect of the mandible was exposed. After identifying and protecting the inferior alveolar neurovascular bundle, a bilateral sagittal split osteotomy was performed with a surgical saw. A standard Le Fort I incision was performed in the mucosa. This was followed by a Le Fort I osteotomy using a surgical saw. The maxilla was downfractured and mobilized. A 3-piece maxillary osteotomy was performed using the surgical saw followed by a thin osteotome by cutting bilaterally in the mesial and distal of the extraction socket of the upper first bicuspid. A strip of bone measuring 6mm was removed from each side. This was done to facilitate the posterior repositioning of the anterior segment of the maxilla. The maxillary segments were aligned and positioned in the intermediate splint. The patient's occlusion was placed into the intermediate splint, and the patient was placed in an intermaxillary fixation with wires and elastics. The maxilla was fixated in the new position using mini titanium alloy plates and 2.0 screws in the areas of the pyriform rim and maxillary buttress. The intermaxillary fixation and intermediate splint were removed. Attention was then drawn back to the mandible where the bilateral sagittal split osteotomy was completed, the mandible was advanced to 8 mm, and the patient was placed in proper occlusion using the final splint. The mandible was fixed using mini titanium plates and 2.0 screws. The intermaxillary fixation was removed, and the occlusion was checked to be as predetermined in the model surgery preoperatively. The occlusion was passive and reproducible.

**Postoperative Care:** The wound was checked daily for one week for signs of ischemia. The splint was kept in

place for 4 weeks, and the patient was placed on a liquid and pureed diet and sinus precautions. The splint was removed in the clinic, and the occlusion was checked. It was stable and reproducible. **Postsurgical Orthodontic Treatment.** Postsurgical orthodontics was continued after surgery to close minor spaces distal to the cuspids in the upper and lower arches. The goals of this phase of treatment were to rehabilitate and restore the neuromuscular function and get final occlusal settling. Occlusal function and settling was greatly improved through the use of intermaxillary elastics. Occlusal selective grinding was also done to finalize the occlusion. The postsurgical phase of orthodontic treatment continued for 8 months. ( Fig.1 and Fig.2)

### Results

Both the gummy smile and lips incompetence were greatly improved. The patient profile showed a marked improvement. Although the occlusion and facial esthetics were greatly improved, the results were not that perfect. The patient started to develop some carious lesions. In addition to this, the patient started to feel distressed due to the lengthy treatment time. That is why we decided to debond, although the results were less than ideal, to enhance both the dental brushing as well as the fast psychological adaptation.

### References

1. Sinclair P M. Orthodontic considerations in adult surgical orthodontic cases," *Dental Clinics of North America*, vol. 32, no. 3, pp. 509–528, 1988.

2. Dryland Vig K., Ellis E. Diagnosis and treatment planning for the surgical-orthodontic patient," *Clinics in Plastic Surgery*, vol. 16, no. 4, pp. 645–658, 1989.
3. Neeley W W, Dolce C, Hatch J P, Van Sickels J E., Rugh J D. Relationship of body mass index to stability of mandibular advancement surgery with rigid fixation. *American Journal of Orthodontics and Dentofacial Orthopedics*, vol. 136, no. 2, pp. 175–184, 2009.

**Corresponding Author**

Dr. G . Vivek Reddy MDS  
Senior Lecturer  
Department of Orthodontics,  
Narayana Dental College and Hospital,  
Nellore.  
Email:gv07375@gmail.com  
Phone No: 919391046354