

SURGICAL INTERVENTION AND HISTOMORPHOLOGIC SPECTRUM OF PERIPHERAL OSSIFYING FIBROMA : A 1 YEAR FOLLOW UP CASE REPORT

¹ Tanuja B ¹	¹ Post Graduate
² Krishna Mohana Reddy K	² Professor and Head
³ Hemakumar C H	³ Post Graduate
⁴ Himabindu L	⁴ Post Graduate

^{1,2,3,4} Department of Periodontology, G.PullaReddy Dental College and Hospital, Kurnool, Andhra Pradesh, India.

ABSTRACT Localised gingival enlargements are commonly seen in the oral cavity. Most of these lesions are reactive and non-neoplastic in nature. Clinically it is always not possible to differentiate one specific gingival enlargement from other. Confirmatory diagnosis is made by histologic analysis. Peripheral ossifying fibroma(POF) is one such entity the confirmatory diagnosis of which is made by histopathological features. It is a reactive benign lesion. The present case report describes a 20- year- old male, who visited the Department of Periodontology with the chief complaint of swelling of gums in the upper front teeth region since 3 months. His past dental history reveals that he had similar type of overgrowth 1year back and had undergone surgical excision 6months back. Intraoral examination revealed a solitary, pedunculated mass involving interdental papilla in relation to 11,21. His intraoral radiograph showed boneloss in relation to 11,21. Surgical excision of the lesion was done by scalpel method followed by histopathologic examination for confirmatory diagnosis. As the overgrowth was re-occurred in this patient the present case report mainly emphasis about the surgical procedure to be done and the close post operative follow up required.

KEY WORDS: Peripheral ossifying fibroma, peripheral giant cell granuloma, peripheral cemento - ossifying fibroma.

INTRODUCTION

There are two variants of ossifying fibromas, central and peripheral. The central variant arises from the endosteum or periodontal ligament near to the root apex and expands from the medullary cavity of the bone, whereas peripheral type occurs exclusively on the soft tissue covering the alveolar process¹. The peripheral ossifying fibroma (POF) accounts for 3.1% of all oral tumors² and for 9.6% of all gingival lesions.³ Peripheral ossifying fibroma(POF) exclusively found on the gingiva and not in any other region of oral mucosa⁴. Its colour varies from pale pink to red and is either pedunculated or sessile⁵ and the most common site is the interdental papilla area⁴. It may cause drifting of the adjacent teeth, and even minimal bone resorption can be seen beneath the lesion^{6,7,8}. It is found most frequently in teenagers and young adults. Females are 2 to 4 times more commonly affected than males between the age group of 25 to 35 years^{3,5,9,10}. POF represents a reactive benign lesion of connective tissue and is a separate entity and not a soft tissue counterpart of central ossifying fibroma^{6,9}. Some investigators believe that the lesion is nevertheless odontogenic in origin, as it has being derived from the periodontal ligament, especially since it occurs only on the gingiva and may contain oxytalin fibres. Presently however

its exact derivation is still uncertain¹¹. In the vast majority of cases, there is no apparent underlying bone involvement visible on the roentgenogram. However, on rare occasions, there does appear to be superficial erosion of the bone. A possibility of tooth migration due to the presence of a peripheral cemento-ossifying fibroma has been reported¹²

Case report

A 20 year old male patient visited the Department of Periodontics, G.PullaReddy Dental College and Hospital, Kurnool with a history of a swelling of gums in the upper front teeth region since 3 months. Initially the lesion was small peanut sized but it slowly progressed to current size. His past dental history reveals that he had similar type of overgrowth 1 year back and had undergone surgical excision 6months back. As reported by the patient, swelling was interfering with his deep bite and esthetically unpleasant appearance. History of bleeding while brushing and also sometimes during mastication. Past medical and family history was non-contributory.

Clinical Examination

Intraoral examination of the lesion revealed a solitary, pedunculated mass involving interdental papilla in relation to 11,21 (Fig .1 and Fig .2). The lesion was pale pink in colour with reddish margins, surface was smooth , extending approximately 1cm x1.2cm apico-coronally and mesiodistally respectively .On palpation, it was non-tender and firm in consistency. The lesion was not fixed to the underlying structures.

Radiographic Examination

IOPA examination in relation to 11 and 21 regions showed horizontal bone loss with spacing between the incisors (Fig.3)

Provisional Diagnosis

A provisional diagnosis of fibroma was given.

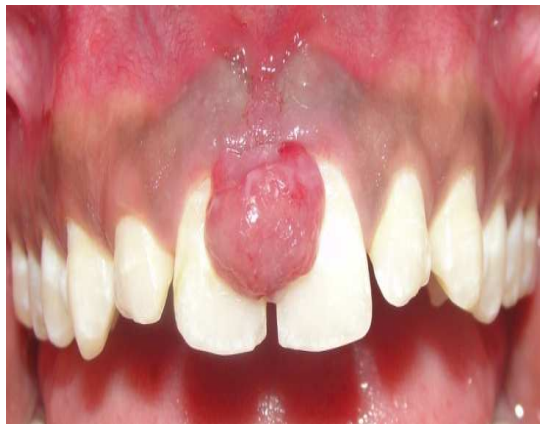

Fig. 1. Clinical presentation of the lesion with respect to 11 and 21

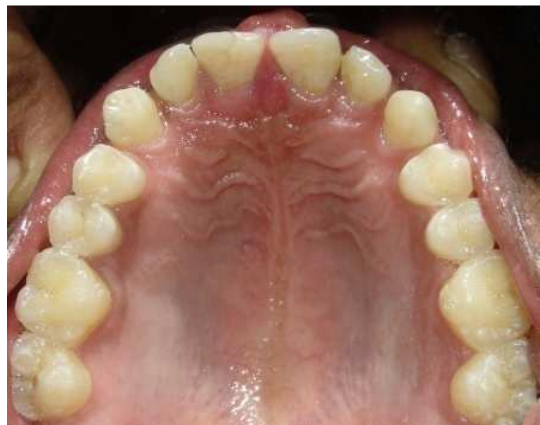

Fig. 2. Clinical presentation of the lesion, palatal view

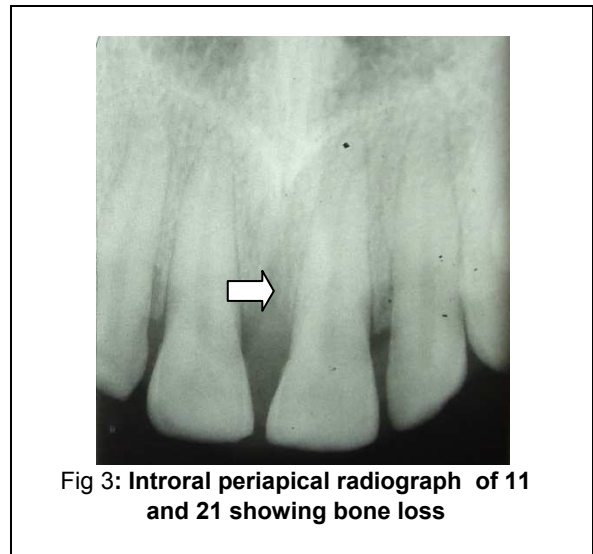


Fig 3: Intraoral periapical radiograph of 11 and 21 showing bone loss

Differential Diagnosis

The following differential diagnoses were made:

1. Irritational fibroma(Epulis)
2. Peripheral Ossifying fibroma
3. Pyogenic Granuloma,
4. Peripheral giant cell granuloma (PGCG)
5. Lipoma

Treatment

Thorough scaling and root planning was performed to eliminate the irritational factors and patient recalled after a week, Consent for the surgical procedure was obtained from the patient after proper counseling. Under local anesthesia, sulcular incision was given with no 15 blade in relation to 11 and 21 and a full thickness flap was elevated, to prevent recurrence the whole growth was surgically excised involving the underlying periosteum followed by thorough scaling and root planning[Fig 4]. Then flap was approximated and interrupted suturing done with 3-0 silk suture material (Fig. 5). Periodontal dressing (Coe-Pack) was placed at the treated site for patient's comfort (Fig.6). patient was given postoperative instructions and was prescribed with systemic antibiotic (Cap amoxicillin 500mg TID) for 5 days, analgesic (Tab Ketorolac Tromethamine 10mg BD) for 3 days and antimicrobial rinse (0.2% chlorhexidine gluconate twice-a-day for 1 week). He was recalled, after 1 week for follow-up. The excised tissue (Fig.7) was placed in 10% neutral buffered formalin and sent for the histopathologic examination to the department of Oral and Maxillofacial pathology.

Microscopic examination showed ulcerated stratified squamous epithelium of variable thickness with underlying cellular fibrous connective tissue. Within the connective tissue collagen fiber bundles were seen arranged

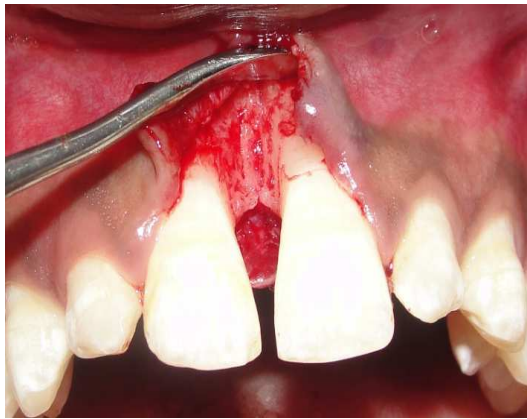


Fig. 4. Immediately after excision of overgrowth, loss. surgical debridement and root planning.

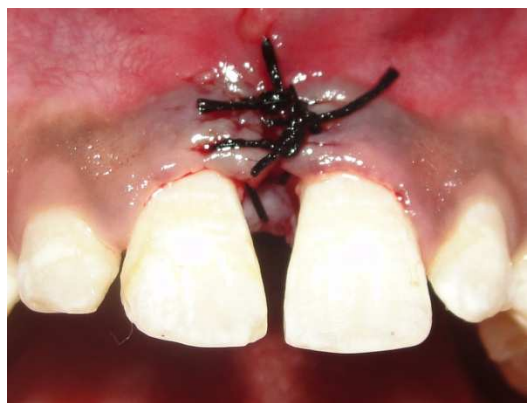

Fig.5: Flap approximation and sutured

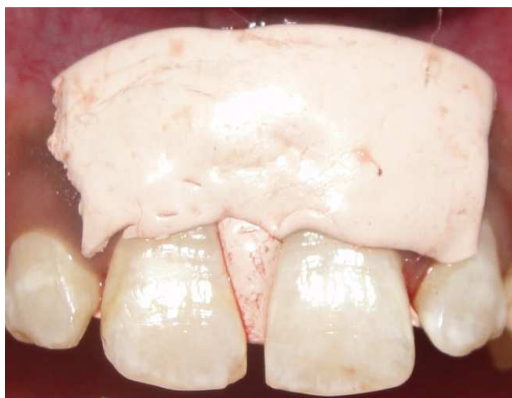

Fig . 6 . Periodontal dressing placed

irregularly and varying sizes of bony trabeculae with osteocytes within their lacunae were evident. At few areas round to ovoid basophilic particles resembling the cementicles with numerous chronic inflammatory cells predominantly lymphocytes were also evident. The histopathological features were diagnostic of peripheral ossifying fibroma (**Fig 8**).

At 1 week post-operative visit, patient presented for suture and periodontal dressing removal and follow-up examination. Recovery was uneventful with a satisfactory healing [Fig 9]. Patient is on regular follow-up at 6 months and 1 year post-operative without any recurrence (**Fig. 10 and Fig.11**)

DISCUSSION

The term peripheral ossifying fibroma was coined by Eversol and Rovin in 1972¹³. Females are most commonly affected than males. Most commonly seen in the younger age group. Incisor- cuspid region of the maxillary arch is the most common site. It usually appears as a painless mass on gingiva measuring not exceeding 3 cm. It can be sessile or pedunculated. Colour of the lesion varies from red to pink i.e earlier lesions appears red and having irregular surface and older lesions appears pink and having smooth surface. Surface may be ulcerated¹⁴.

The POF, as noticed in this case, is a focal, non-neoplastic, reactive tumor-like growth of soft tissue that often arises from the interdental papilla[9,15]. It is believed to comprise about 2 percent of all oral tumors and about 9 percent of all growths that arise from the gingiva⁹.

Etiology and pathogenesis of POF is quite controversial. The reasons for the development of lesion includes several local etiological factors, such as subgingival plaque and calculus, trauma, poor-quality dental restorations, dental appliances, food lodgment, microorganisms, masticatory forces, cells of periodontal ligament PdL[16] and iatrogenic factors^{5,17,18}.

The reason why PdL has been considered as one of the etiological factors of POF is because of its sole occurrence in the gingiva (interdental papilla), the closeness of gingiva to the PdL, and the occurrence of oxytalan fibers within the mineralized matrix of few lesions¹⁶.

The radiographic findings of Peripheral ossifying fibroma vary from case to case. Calcifications of the lesion which gives a radiopaque picture in the radiograph are mostly concentrated in the central area of the lesion, but not all lesions shows the presence of radiopacities^{16,19,20}.

Radiographically, it is not possible to identify the involvement of the underlying bone but rarely one can notice superficial erosion of bone[20]. In our case, there was horizontal bone loss in relation to 11 and 21 along with superficial erosion of bone. Usually POF lesion appears small and does not require imaging beyond radiographs.

A confirmatory diagnosis of POF is made by histopathologic evaluation of biopsy specimens. POF histologically appears as a mass of cellular fibroblastic connective tissue which is non encapsulated and

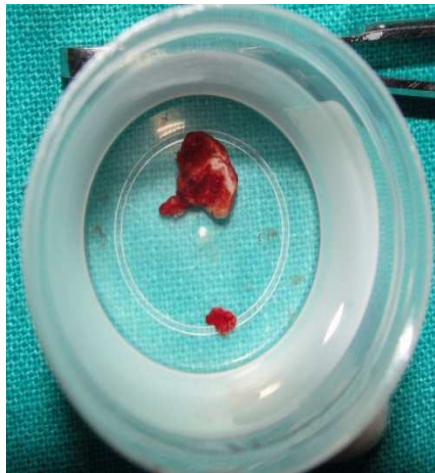


Fig. 7. Excised tissue placed in 10% neutral buffered formalin solution

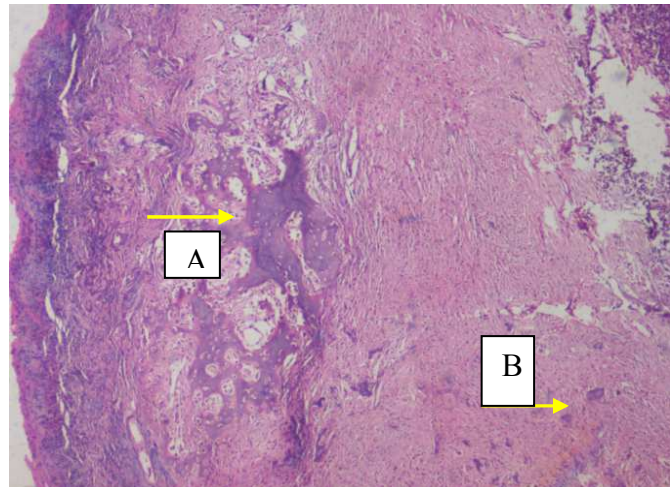


Fig. 8. Histopathological examination showing ulcerated stratified squamous epithelium with underlying ossification and lymphocytic infiltration (10×, H&Estain). A – Bony trabeculae, B - Cementicle

mesenchymal origin¹⁵. It is covered with stratified squamous epithelium, and ulcerated in about 23%–66% of cases[9,21]. Most of these ulcerated lesions occur in patients in the second decade^{5,21}. POFs contain areas of fibrous connective tissue, endothelial proliferation and mineralization. In the areas of ulceration, endothelial proliferation can be profuse which can be misleading in clinical diagnosis, as the lesion may appear to be a pyogenic granuloma[9]. The mineralization of POF varies, occurring in approximately 23%²² 35%² or 50%–75%^{9,21,23} of cases according to published reports. Mineralization can vary between cementum-like material, bone (woven and lamellar) and dystrophic calcification^{9,21,23}.

Various treatment options for POF include surgical excision by scalpel, laser or radial/electrosurgery[24]. The carbon dioxide laser can effectively excise the lesion and even allow diagnostic microscopic evaluation with a minimal distortion of the biopsy sample[25]. The advantages of laser excision are minimal post-surgical pain and no need for suturing the biopsy site. However because of precise tissue destruction it results in partial or incomplete removal of the base of the pathologic lesion, which can lead to recurrence²⁶. Thus, surgical excision including the involved periodontal ligament and periosteum is the best treatment option⁷ which was performed in this case.

CONCLUSION

POF is a reactive non-neoplastic lesion of connective tissue which is slow progressing lesion usually with limited growth. Because of the lack of symptoms makes it to progress for a long period of time before patients seek any

form of treatment. A slowly progressive pink soft tissue gingival over-growth in the anterior maxillary arch of an adolescent should raise suspicion of a POF. Clinically it was difficult to differentiate POF from pyogenic granuloma, PGCG, or odontogenic tumors, radiographic and histologic examination is a must to confirm its diagnosis. As the overgrowth was reoccurred in this patient may be because of incomplete removal of the lesion previously and now the treatment consists of surgical excision of the lesion including the periosteum and scaling of adjacent teeth was performed. Because of the high recurrence rate of 8-20%, regular postoperative follow-up is required. Patient was under regular follow-up[1Year] without any reoccurrence.

conflicts of interest :

There is no conflict of interest in regard to the diagnosis, treatment plan by any of the author.

References

1. Singh AP, Raju M S, Mittal M. Peripheral ossifying fibroma: A case report. Journal of Nepal dental association 2010; 11, Jan-june 70-72.
2. Kenney JN, Kaugars GE, Abbey LM. Comparison between the peripheral ossifying fibroma and peripheral odontogenic fibroma. J Oral Maxillofac Surg 1989;47:378-82.
3. Walters JD, Will JK, Hatfield RD, Cacchillo DA, Raabe DA. Excision and repair of the peripheral ossifying fibroma: a report of 3 cases. J Periodontol 2001 Jul;72(7):939-944.
4. Kerr AR, Phelan JA. Benign lesions of the oral cavity. In: Greenberg MS, Glick M, Ship JA, editors.

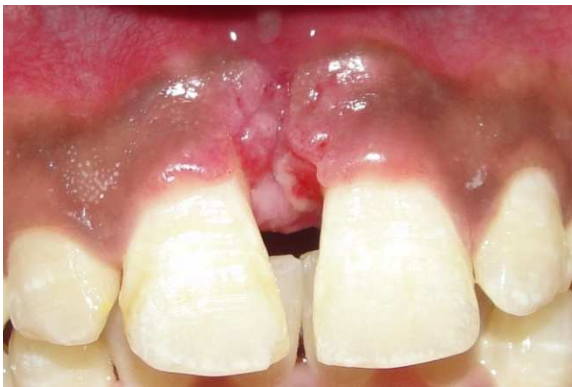

Fig .9.Post-operative 1 week showing uneventful healing

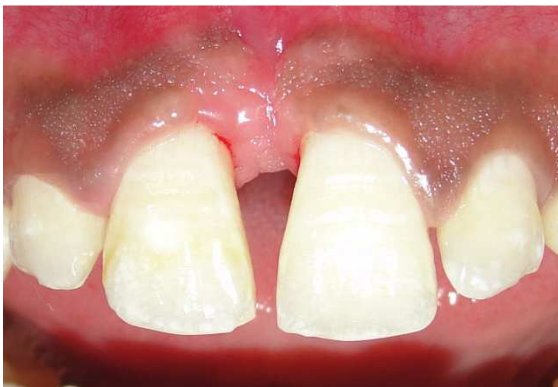

Fig .10.Post-operative 6 months with no recurrence of the lesion

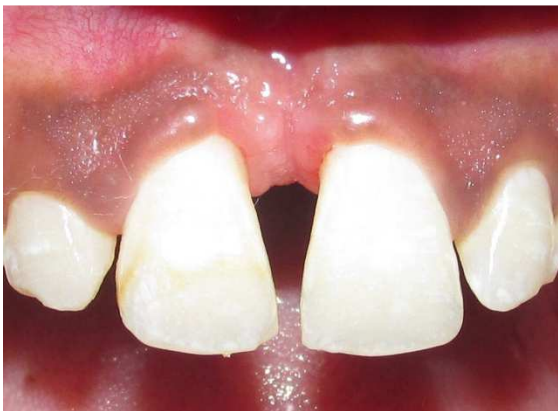

Fig.11. 1 Year post-operative with no recurrence the lesion

Burket's oral medicine. 11th ed. Hamilton: BC Decker Inc.; 2008. p. 133-134.

5. Eversole LR, Rovin S. Reactive lesions of the gingival. *J Oral Pathol* 1972;1(1):30-38.
6. Neville BW, Damm DD, Allen CM, Bouquot JE. Soft tissue tumors. In: Neville BW, Damm DD, Allen CM, Bouquot JE, editors. *Oral and maxillofacial pathology*. 3rd ed. West Philadelphia (PA): Saunders; 2009. p. 521-523.

7. Poon CK, Kwan PC, Chao SY. Giant peripheral ossifying fibroma of the maxilla: report of a case. *J Oral Maxillofac Surg* 1995 Jun;53(6):695-698.
8. Wood NK, Goaz PW. Peripheral oral exophytic lesions. In: Wood NK, Goaz PW, editors. *Differential diagnosis of oral and maxillofacial lesions*. 5th ed. St Louis (MO): Mosby; 2006. p. 143-144.
9. Bhaskar SN, Jacoway JR. Peripheral fibroma and peripheral fibroma with calcification: report of 376 cases. *J Am Dent Assoc* 1966 Dec;73(6):1312-1320.
10. Prasad S, Reddy SB, Patil SR, Kalburgi NB, Puranik RS. Peripheral ossifying fibroma and pyogenic granuloma. Are they interrelated? *N Y State Dent J* 2008 Mar;74(2):50-52.
11. R.Rajendran, B.Sivapathasundharam. *Shafer's textbook of oral pathology- 5th edition*.
12. Delbem AC, Cunha RF, Silva JZ, Soubhia AM. Peripheral cementoossifying fibroma in child. a follow-up of 4 years. Report of a case. *Eur J Dent* 2008;2:134-7.
13. Reddy GV, Reddy J, Ramlal G, Ambati M. Peripheral ossifying fibroma: Report of two unusual cases. *Indian J Stomatol* 2011;2:130-3.
14. Sharma S, Anamika S, Ramachandra SS. Peripheral ossifying fibroma: A clinical report. *Compend Contin Educ Dent* 2011;32:E86-90.
15. Gardner DG. The peripheral odontogenic fibroma: an attempt at clarification. *Oral Surg Oral Med Oral Pathol* 1982;54:40-8.
16. Kumar SK, Ram S, Jorgensen MG, Shuler CF, Sedghizadeh PP. Multicentric peripheral ossifying fibroma. *J Oral Sci* 2006 Dec;48(4):239-243.
17. Miller CS, Henry RG, Damm DD. Proliferation mass found in the gingival. *J Am Dent Assoc* 1990 Oct;121(4):559-560.
18. Mesquita RA, Orsini SC, Sousa M, de Araújo NS. Proliferative activity in peripheral ossifying fibroma and ossifying fibroma. *J Oral Pathol Med* 1998 Feb;27(2):64-67.
19. Marx RE, Stern D. *Oral and maxillofacial pathology: a rationale for diagnosis and treatment*. Chicago: Quintessence; 2003. p. 23-25.
20. Flaitz CM. Peripheral ossifying fibroma of the maxillary gingival. *Am J Dent* 2001 Feb;14(1):56.
21. Buchner A, Hansen LS. The histomorphologic spectrum of peripheral ossifying fibroma. *Oral Surg Oral Med Oral Pathol* 1987; 63(4):452-61.
22. Zhang W, Chen Y, An Z, Geng N, Bao D. Reactive gingival lesions: a retrospective study of 2,439 cases. *Quintessence Int* 2007; 38(2):103-10.
23. Zain RB, Fei YJ. Fibrous lesions of the gingiva: a histopathologic analysis of 204 cases. *Oral Surg Oral Med Oral Pathol* 1990; 70(4):466-70.
24. Rossmann JA. Reactive lesions of the gingiva: Diagnosis and treatment options. *Open Pathol J* 2011;5:23.
25. Bornstein MM, Winzap-Kalin C, Cochran DL, Buser D. The CO2 laser for excisional biopsies of oral

lesions: A case series study. Int J Periodontics Restorative Dent 2005;25:221-9.

26. Tamarit-Borras M, Delgado-Molina E, Berini-Aytes L, Gay-Escoda C. Removal of hyperplastic lesions of the oral cavity. A retrospective study of 128 cases. Med Oral Patol Oral Cir Bucal 2005;10:151-62.

Corresponding Author

Dr. Tanuja.B
Department of Periodontology,
G. Pulla Reddy Dental College and Hospital
Kurnool, Pin: 518007
Andhra pradesh
Cell: 9491240968
e-mail: dr.tanujareddy@gmail.com