

SURGICAL AND ORTHODONTIC MANAGEMENT OF DENTAL CYCLOPS: A CASE REPORT

¹ Bharath Reddy.P² Rani M.S³ Santosh R⁴ Shefali Pareekh¹ Reader² Professor and Head³ Associate Professor⁴ post Graduate Student^{1,2, 3} Department of Orthodontics, V.S Dental College and Hospital, V.V Puram, K.R Road, Bengaluru-4, Karnataka, India.**ABSTRACT**

Impacted Central Incisor tooth is a common finding in the Orthodontic practice. But managing of Impacted Incisor which is unfavorable with Dilaceration is a tough task. We are presenting a case of Maxillary impacted incisor with Dilaceration.

KEY WORDS: Maxillary Dental Cyclopes

INTRODUCTION

There is a swing in the decision of surgical management of impacted teeth from oral surgeon to Orthodontist. Impaction of a permanent tooth is rarely diagnosed during the mixed dentition period. An impacted central incisor is usually diagnosed when there is delay in the eruption of the tooth.¹ Many patients with impacted maxillary central incisors are referred to orthodontists by General Practitioners or Pediatric dentists, because Parents are concerned about the impaction of an incisor in the early mixed dentition, the impaction of maxillary central incisors is not very common.²⁻⁴ Tooth impaction may result from a number of local causes such as supernumerary teeth^{5,7}, odontome, ectopic position of tooth bud, dilacerations and arrested root development. Maxillary central incisor impacted at the apical third of the contra lateral incisor root, should be managed by the surgical-orthodontic approach, as spontaneous eruption is unlikely.⁸ Careful planning is required when moving an impacted tooth by orthodontic treatment. Impacted teeth can be properly positioned with orthodontic traction.⁹⁻¹¹

Case report

An eleven year old boy reported to the department of Orthodontics at our institution in September 2007 complaining of pain in the upper anterior region. On examination when the patient smiled, a single

central incisor was seen which looked like "Dental Cyclops" (Non Syndromal) (**Fig.1**).¹² On intra oral examination, 11 was found missing and 12 was migrated to the place of 11 leaving very minimal space for the permanent tooth. 21 was also migrated towards missing 11 region giving the appearance of Cyclops tooth (**Fig.2**). On palpation there was a bulge which was felt in the sulcus of the maxillary anterior region next to the labial frenum. There was no history of trauma. An IOPA revealed an impacted right central incisor. To know the morphology and position of the impacted tooth, OPG, Lateral Cephalogram and an occlusal radiograph were taken (**Fig.3**). Impacted tooth appeared like a Bulls Eye in the OPG; Lateral Cephalogram showed that the impacted incisor was just behind the anterior nasal spine and Occlusal radiograph showed dilaceration of the root (**Fig.3**).

Treatment

Fixed mechanotherapy was started and 0.016 inch round Niti wire was given to align the teeth and then 0.019X0.025 inch stainless steel rectangular wire given with open coil spring between 21 and 12 to gain the space for impacted tooth. The impacted tooth was exposed using Open Eruption Technique with window.¹² Circular section of the overlying

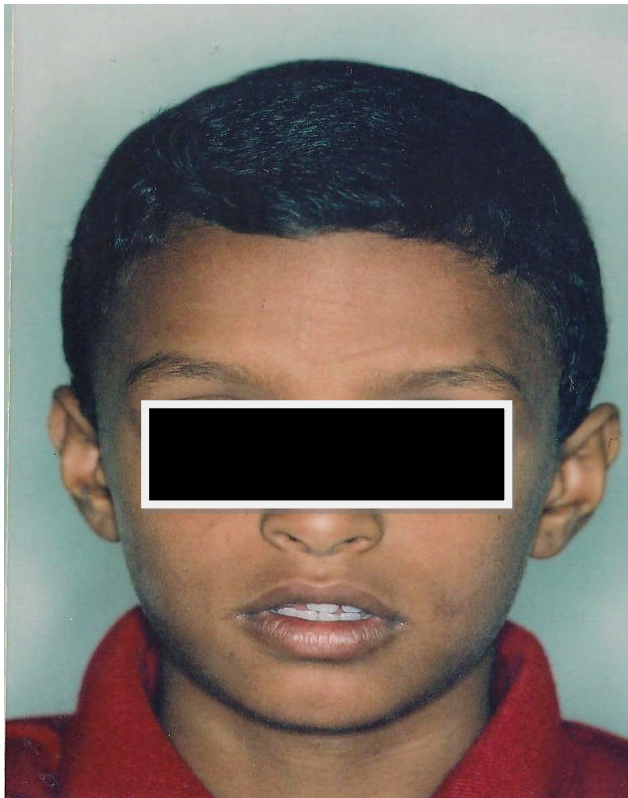

Fig.1. Extra oral View of the patient

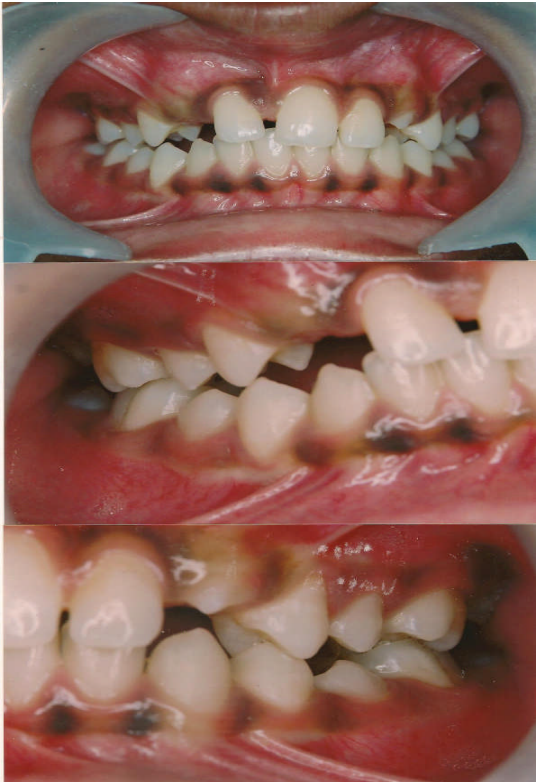

Fig. 2. Intra oral View of the patient

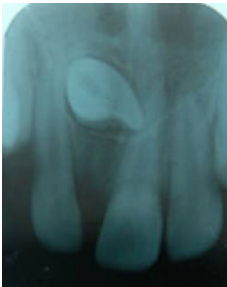

Fig.3a. IOPA

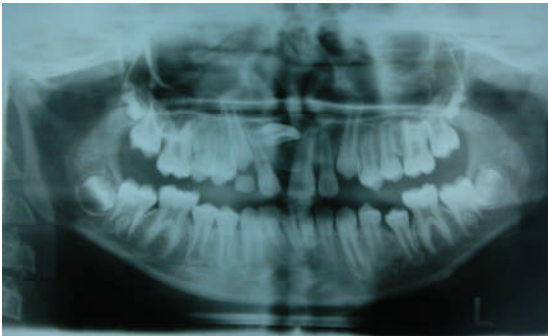


Fig.3b.OPG

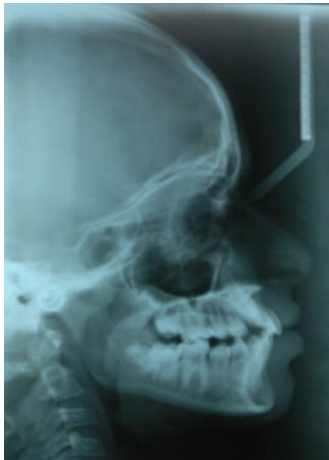

Fig.3c.Lateral cephalogram

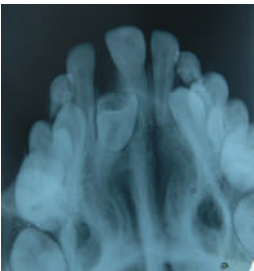


Fig.3d.Occlusal View

Fig.3a- Fig.3d. Radiographs of the patient

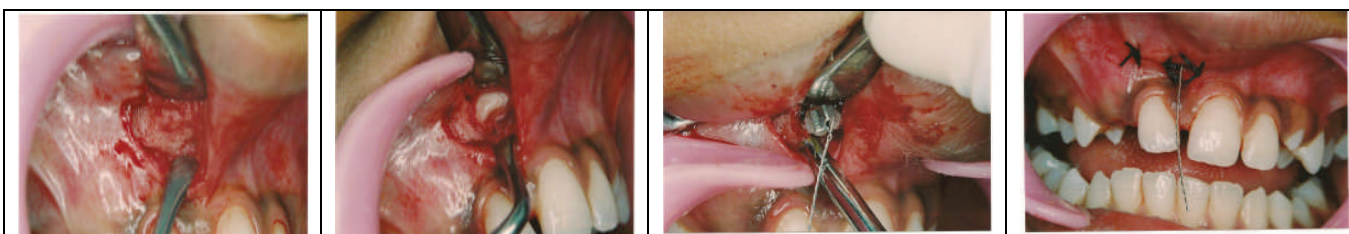

Fig.4. surgical exposure and bonding of the attachment

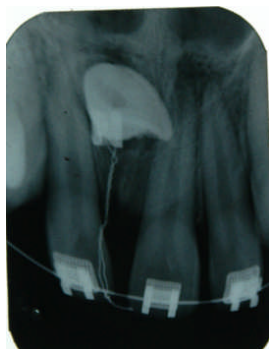

Fig.5.Traction force

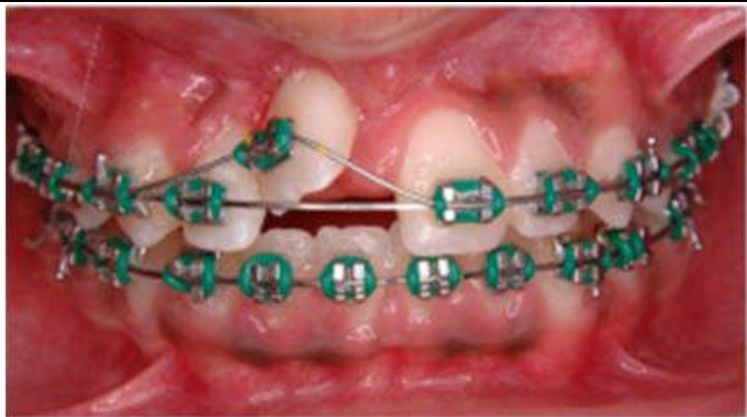


Fig.6.Alignment in progress

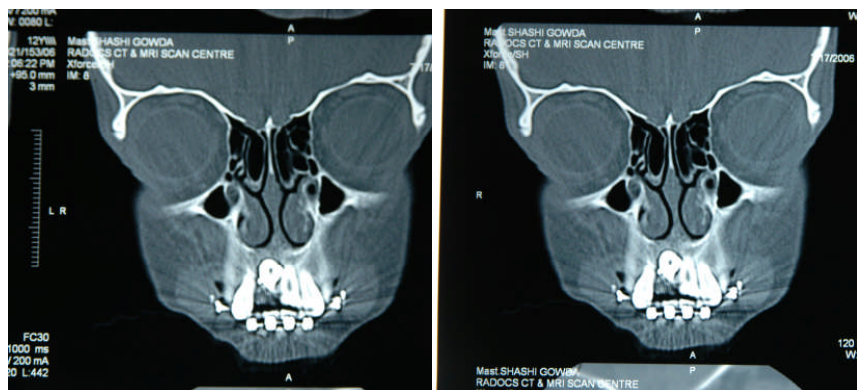


Fig.7. CT scan showing the dilaceration of 11

mucosa and the bony covering was surgically removed. Distoincisor angle of the incisor was exposed. A Begg bracket was bonded on to the exposed incisor and was ligated with 0.009 inch ligature wire for traction. The flap was repositioned and sutured to gain good length of attached gingiva (**Fig.4**). The attachment was ligated to the arch wire and traction was given to guide the tooth in to the position (**Fig.5**). After the tooth was out of the bone, a sectional Tandem wire using 0.016 Niti wire was given over the 0.019X0.025 SS rectangular wire to align the impacted tooth into the arch (**Fig.6**). Three dimensional CT scan was taken to localize the dilaceration of the root so that it does not impinge on the adjacent teeth while traction was given. ¹³CT

images showed distal dilaceration of the root (**Fig.7**). After the eruption of incisor into the arch, finishing with 0.016 inch stainless steel wire is done. As very light forces were used for the traction, there was no discoloration and root resorption hence root canal treatment or apicoectomy was not required (**Fig.8**). Post treatment IOPA showed good length of inter dental bone and root (**Fig.9**).

Discussion

Orthodontists may generally opt to extract impacted maxillary incisors with severe dilaceration because of difficulties in its management. Most patients probably would choose extraction and replacement

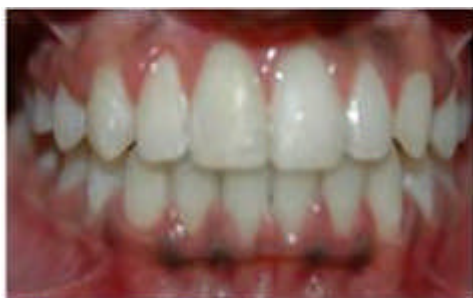

Fig.8. Post treatment photographs.

by Prosthesis. However, if extraction of the impacted central incisor and restoration with a bridge or an implant is planned, orthodontic traction of that tooth into the proper position should be performed initially to improve esthetics and to achieve and maintain an acceptable bone height.¹ Though it is longer duration of treatment, it is beneficial as the growth is not impeded. The present case did not use the closed-eruption surgical technique, which elevates a flap and returns it to the original location after placing an attachment on the impacted tooth. The oral surgeon removed a minimum area of buccal mucosa to locate the tip of the impacted incisor. So that the repositioned incisor would present an acceptable gingival contour and attached gingiva.

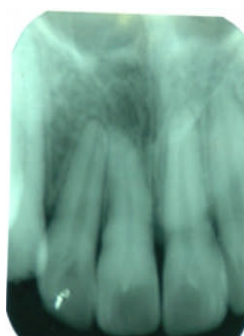


Fig.9. Posttreatment radiographs.

The time taken to finish the treatment was two years seven months. Jerusalem Hypothesis could be the possible etiology for the impaction of incisor¹² as the patient did not give the history of trauma.

CONCLUSION

Surgical exposure and orthodontic management of a severely dilacerated impacted incisor is a clinical challenge. Timely intervention with perfect planning of the case makes the treatment easy with best

results. Results showed good stability with excellent esthetics.

References

1. Setsuko Uematsu, DDS, PhD; et al Orthodontic Treatment of an Impacted Dilacerated Maxillary Central Incisor Combined with Surgical Exposure and Apicoectomy Angle Orthod 2004;74:132–36.
2. Becker A. Early treatment for impacted maxillary incisors. Am J Orthod Dentofacial Orthop. 2002;121:586–87.
3. Lin YTJ. Treatment of an impacted dilacerated maxillary central incisor. Am J Orthod Dentofacial Orthop. 1999;115:406–09.
4. Archer LE. Composites. Oral and Maxillofacial Surgery. 5th ed. Philadelphia, Pa: WB Saunders Company; 1975: 250–390.
5. Howard RD. The unerupted incisor. Dent Pract Dent Rec. 1967; 17: 332-42.
6. Brin I, Zilberman Y, Azaz B. The unerupted maxillary central incisor: review of its etiology and treatment. J Dent Child 1982; 43: 352-56.
7. Zilberman Y, Malron M, Shteyer A. Assessment of 100 children in Jerusalem with supernumerary teeth in the premaxillary region. J Dent Child 1992; 59: 44-47.
8. Dalia Smaliene, Antanas Sidlauskas, Jevgenija Bucinskiene. Impaction of the central maxillary incisor associated with supernumerary teeth: Initial position and spontaneous eruption timing. Baltic Dental and Maxillofacial Journal, 2006; 8: 103-07.
9. Wasserstein A, Tzur B, Brezniak N. Incomplete canine transposition and maxillary central incisor impaction a case report. Am J Orthod Dentofacial Orthop. 1997;111:635–39.
10. Kolokithas G, Karakasis D. Orthodontic movement of dilacerated maxillary central incisor. Am J Orthod. 1979;76:310–315.
11. Tanaka E, Watanabe M, Nagaoka K, Yamaguchi K, Tanne K. Orthodontic traction of an impacted maxillary central incisor. J Clin Orthod. 2001;35:375–78.
12. Adrian Becker in The Orthodontic Treatment of Impacted Teeth. Informa Health Care publishers, 2nd ed, 2007, pp 143, 240.
13. Kee-Deog Kim, Axel Ruprecht, et al. Personal Computer-Based Three-dimensional computed tomographic images of the teeth for evaluating supernumerary or ectopically impacted teeth. Angle Orthod. 2003; 73:614–621.

Corresponding Author

Bharath Reddy.P M.D.S

Lecturer, Department of Orthodontics,
V.S Dental College and Hospital
V.V Puram, K.R Road, Bengaluru-4
Ph:91-988-640-4988
E-mail: bharath.mds@gmail.com