

**RANULA IN THE FLOOR OF THE MOUTH – A CASE REPORT**

<sup>1</sup>.Vamsi Prasad  
<sup>2</sup> RaviRaja Kumar  
<sup>3</sup> Kalpana K

<sup>1</sup>Professor , Department of Periodontics  
<sup>2</sup> Reader , Department of Oral and Maxillofacial surgery  
<sup>3</sup>Professor, Department of prosthodontics

<sup>1,2,3</sup>. St. Joseph Dental College ,Eluru, Andhra pradesh, India.

**ABSTRACT**

Ranulas occur due to extravasation of saliva from one of the 20 ducts that arise from the sublingual gland and empty in to the floor of the mouth or into the anterior portion of wharton's duct. They form a characteristically blue tense vesicle in the floor of the mouth. This paper highlights a case report of ranula in the posterior floor of the mouth that has been successfully treated by marsupialization technique.

**KEY WORDS : Mucocele, Ranula, Marsupialization.**

**INTRODUCTION**

Mucoceles are mucous extravasation phenomena resulting from traumatic severance of salivary excretory ducts or occasionally their spontaneous rupture. The extravasated mucin elicits an inflammatory reaction and fibrosis, resulting in the formation of mucocele<sup>1</sup>. Mucoceles can occur almost anywhere in the minor salivary gland region but are most common in the lower lip. They also occur related to the sublingual gland, called *ranula* and even in the parotid gland, called a *sioloccele*<sup>2,3</sup>.

**Case report**

A 9 year old young female patient reported to the outpatient department with a chief complaint of painless swelling below the tongue on the left side of the oral cavity for the past 2 months. The swelling has gradually increased in its size to attain the present status. On examination, a 2 x 5cm bluish, fluctuant swelling was found in the posterior floor of the mouth on the left side (**Fig. 2**). The swelling is painless on palpation. Based on the clinical

picture the case was provisionally diagnosed to be *ranula*. Clinical and radiographic evaluation of the patient showed mixed dentition period (**Fig.4**). Aspiration biopsy yielded thick, viscous fluid and histopathological examination (HPE) revealed it to be mucous (**Fig. 3**).

After routine preoperative investigations, marsupialization of ranula is carried out under local anesthesia(Fig.5). The cavity resulting from marsupialization was packed with betadine roller gauze pack and the pack size was gradually cut short as per the obliteration of the defect. A small portion of the tissue that has been removed during the procedure was submitted to HPE for confirmation. HPE report confirmed the specimen to be ranula. The microscopic appearance of ranula is similar to that of a mucocele in other locations. The spilled mucin elicits a granulation tissue response that typically contains foamy histiocytes. The case was followed for 2 months at weekly intervals with no postoperative complications.

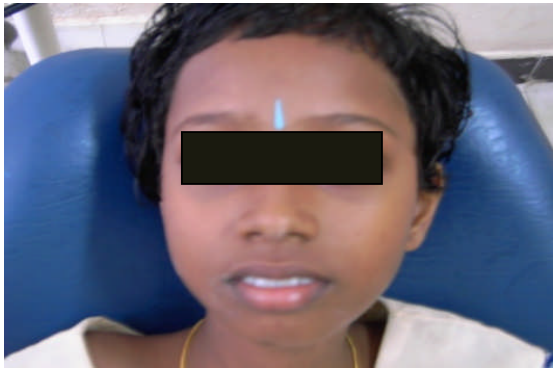

Fig.1.Extraoral pretreatment photographs

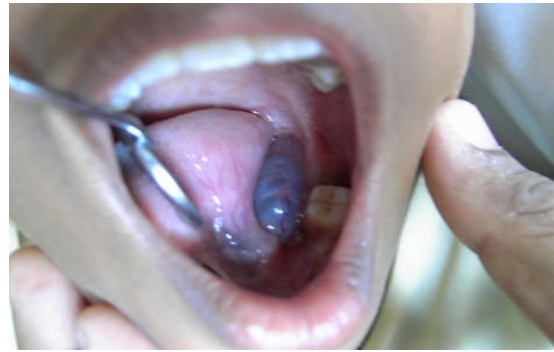

Fig.2.Intraoral\_photo

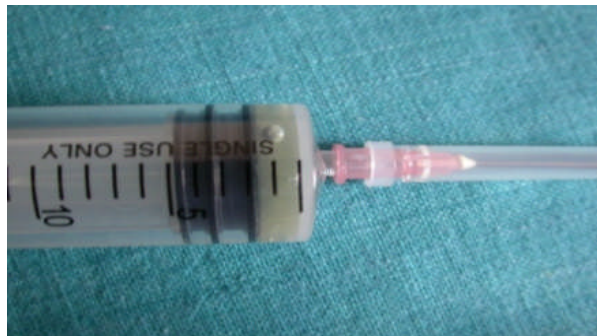

Fig.3.Aspirated mucous

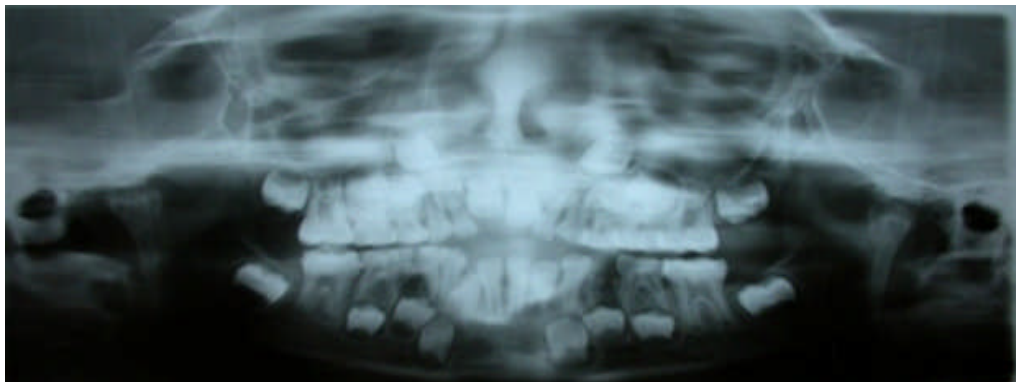


Fig.4.OrthoPantomograph

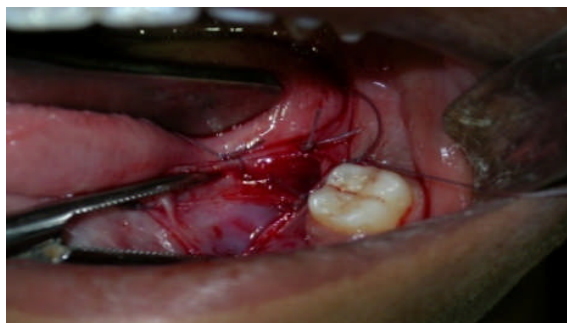

Fig.5. Marsupialization

## Discussion

Ranula is a term used for mucocoeles that occur in the floor of the mouth. The typical size of a ranula and the firmness of the floor of the oral mucosa together resemble a frog's belly, hence the name 'ranula' which refers to the frog's genus, *Rana*<sup>4</sup>.

The source of mucin spillage is usually from the sublingual gland; but ranulas also may arise from the submandibular duct or from the body of the sublingual gland, although smaller lesions can develop along the sublingual plica from the superficial *duct of rivinus* of the gland.<sup>5</sup> Some ranulas will attain sufficient fluid pressure as to herniate through the mylohyoid muscle and produce swelling within the neck. These are called "*plunging*" or "*cervical*" ranulas.<sup>6,7</sup> Some become sufficiently large to compromise swallowing or breathing and extend as far as the mediastinum. Imaging studies can be helpful in supporting a diagnosis of plunging ranula and in determining the origin of the lesion. CT and MRI imaging of plunging ranulas that arise from the sublingual gland often exhibit a slight extension of the lesion into the sublingual space referred to as "*tail sign*"- an imaging feature not observed in the lesions that develop from the submandibular gland<sup>8</sup>.

Differential diagnosis of ranula should include dermoid cyst, teratoid cyst and gastro-intestinal heterotopic cyst as they occur more rarely in this area. The firmness and doughy quality of a ranula may suggest a salivary gland tumor of the sublingual gland, a lymphangioma, or a lymphoma and HIV-related lymphadenopathy

Treatment of the ranula consists of excision of fibrous capsule and removal of the feeding sublingual gland or marsupialization.<sup>9</sup> Transoral approaches to the ranula excision should attempt to minimize the risk of damage to small branches of the lingual nerve. The lingual nerve is known to double cross the submandibular duct in the posterior lingual vestibule. It is therefore, at greatest risk for damage in this location.<sup>10</sup>

Marsupialization was opted as treatment choice in our case as the technique is simple and is not associated with damage to the important anatomic structures in this location. Also, there is enough documentation to support this technique as treatment of choice. Sometimes there may be a need to do marsupialization for several times to

resolve a large ranula. But this case does not warranted multiple steps as the postoperative period is uneventful.

## References

1. Anastassov GE, Haiavy J, Solodnik P et.al: Submandibular gland mucocoele: Diagnosis and management, Oral surg Oral med Oral path Oral rad Endod. 2000; 89: 159-63
2. Standish SM, Savage WG: The mucous retention phenomenon, J Oral Surg 1959;17:15-22,
3. Sugeran PB, Savage NW, Young WG: Mucocoele of the anterior lingual salivary glands (Glands of Blandinn & Nuhn): report of 5 cases, Oral surg Oral med Oral path Oral rad Endod , 2000;.90:478-82
4. Cataldo E: Mucocoeles of the oral mucousmembrane, Arch Oto laryngol, 1970;91:360-365
5. Galloway RH Gross PD, Thompson SH et.al: Pathogenesis and treatment of ranula: report of three cases, J Oral Maxillofac Surg , 1989;.47: 299-302
6. Davison MJ, Morton RP, Mc Ivor NP: Plunging ranula: Clinical observations, Head neck 1998:20: 63-8
7. Mahaddevan M, Vasan N: Management of pediatric plunging ranula, Int J pediatr otolaryngol, 2006; 70: 1049-54
8. Kurabayashi T, Ida M, Yasumoto M et.al: MRI of ranulas, Neuro radiology, 2000:42: 917-33
9. Yoshimura Y, Obara S, Kondoh T et.al: A comparison of three methods used for treatment of ranula, J oral Maxillofac surg .1995;53: 280-82
10. Baurmash HD: A case against sublingual gland removal as primary treatment of ranulas, J Oral Maxillofac Surg . 2007; 65:117-121.

## Corresponding Author

**Dr. Vamsi Prasad MDS**  
 Professor  
 Department of Periodontics,  
 St. Joseph Dental College,  
 Eluru  
 Andhrapradesh, India.  
 Ph no: 09393303070  
 Email: vivekanandh.reddy@yahoo.co.in