

## PRE-SURGICAL NASOALVEOLAR MOLDING IN PATIENTS WITH UNILATERAL CLEFTS OF LIP, ALVEOLUS AND PALATE - A CASE REPORT

<sup>1</sup> Akshai Shetty KR<sup>2</sup> Krishnamurthy Bonanthaya<sup>3</sup> Dharma RM<sup>4</sup> Viswapurna P S<sup>1</sup> Professor, Department of Orthodontics<sup>2</sup> Professor, Oral and maxillo facial surgery<sup>3</sup> Professor, Department of Orthodontics<sup>4</sup> In private Practice<sup>1,3</sup> DAPM RV Dental College and Hospital, Bangalore, India.<sup>2</sup> Bangalore Institute of Dental Sciences, Bangalore India<sup>4</sup> Salem- India, Seychelles Islands & Muscat

## ABSTRACT

The case of a newborn male patient with unilateral cleft lip, alveolus and palate with a marked cleft nose deformity is presented. This may lead to an unsatisfactory aesthetic result after primary cheiloplasty and nasoplasty. Five months prior to surgery, the patient was treated with Naso-alveolar molding. The device consisted of an acrylic plate on the maxillary arch to which was attached a wire of 0.032 inch diameter which lifted the nasal dome. The alignment of the alveolar segments creates the foundation upon which excellent results of lip and primary nasal surgery are dependent in the repair of the cleft lip and palate patient. The purpose of this article is to highlight the effectiveness of naso alveolar molding appliance used to direct growth of the alveolar ridge, lips, and nose in the pre surgical treatment of cleft lip and palate. As a result of this appliance, the primary surgical repair of the nose and lip heals under minimal tension, thereby reducing scar formation and improving the esthetic result.

**KEY WORDS:** : Naso alveolar molding; pre surgical treatment; unilateral cleft lip Palate

## INTRODUCTION

Presurgical Othopedics( PSO) is one of the well known components of the management of the cleft lip and cleft palate patients. The goals of pre-surgical naso-alveolar molding was to align and approximate the alveolar cleft segments, to correct the malposition of the nasal cartilage and reduce soft tissue deformity by correcting the nasal tip, alar base and the position of phitrum and columella.<sup>1-7</sup>

A case of cleft lip and lip treated by Naso alveolar moulding is described in this article.

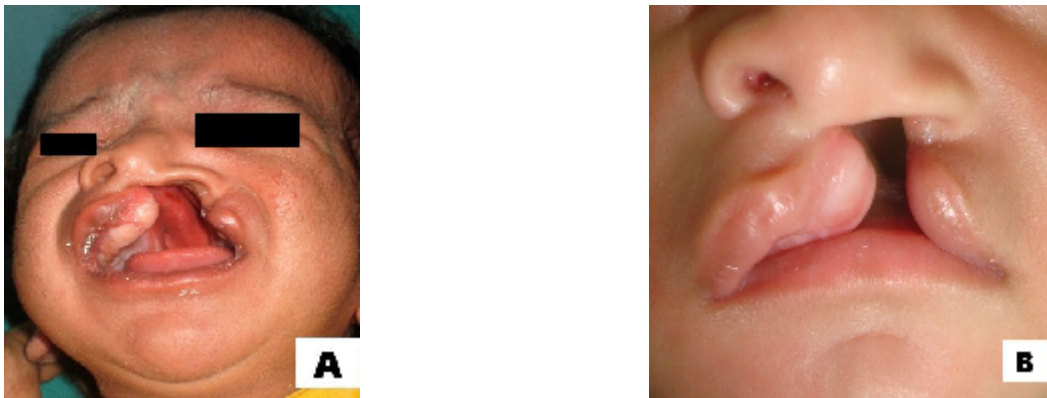
## Case Repot

A family brought their 12-day-old boy with complete uni-lateral cleft lip and palate to our unit for consultation. He had a nasal deformity and a displaced alveolar segment. The columella and nasal septum were inclined over the cleft with base deviated towards the non-cleft side. In addition, nasal tip appeared to be depressed and displaced. The intraoral cleft gap was 10 mm. (**Fig 1 A&B**).

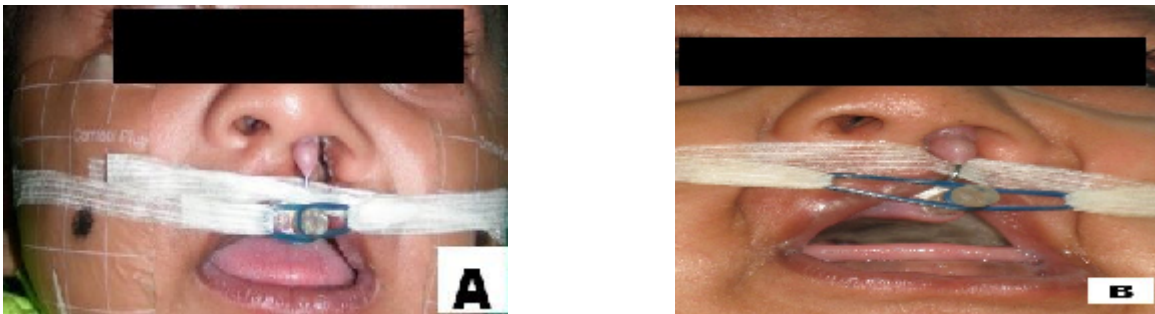
The technique of nasoalveolar moulding followed was Liou's technique (Modified Figueroa's), wherein alveolar and nasal molding are done at the same time, the rationale being the acquired maternal estrogen before birth results in decrease in elasticity and increase in plasticity of cartilages. It has been reported by Matsuo (1984) that the temporary plasticity of nasal cartilage is

believed to be caused by high levels of hyaluronic acid, a component of the proteoglycan intercellular matrix, which is found circulating in the infant for several weeks after birth.<sup>4,8</sup> Matsuo and Hirose (1991) were the first to make the use of this elasticity in correcting the cleft nose deformity by inserting a nostril retainer or conformer to lift the nasal cartilage.<sup>8</sup> So it was decided to do nasal molding as early as possible. At one week after birth the infant was evaluated by the pediatrician and other members of the cleft team.

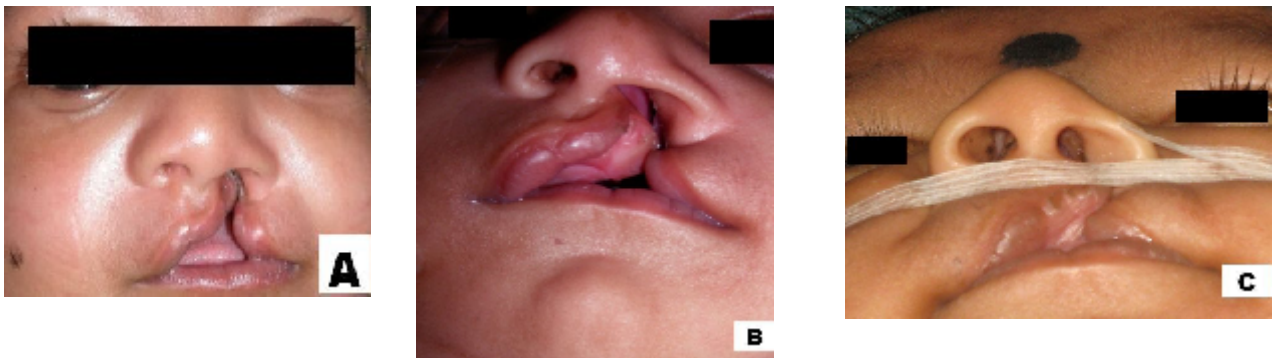
Following the clinical examination, an impression of the intraoral cleft defect was made using an elastomeric material in an infant acrylic impression tray. The impression was taken when the infant was awake in a supine position without anesthesia in the outpatient clinic. The newborn's preoperative orthopedic plate was constructed with auto polymerizing acrylic resin. The plate was inserted into the newborn's mouth when he was 16 days old. It covers the palate and alveolar process. Before delivering the plate, the lip segments are approximated by applying micro pore tapes (nonsurgical lip adhesion) (**Fig-2A**). With the tapes in place the molding plate is inserted into the mouth. The plate is held on the palate and alveolar process through the use of denture adhesive as well as using a tape-elastics system applied externally to the cheeks (**Fig-2B**).



**Fig .1 A & B:Cleft nasal deformity; Prior to naso alveolar molding. Note the nasal cartilage deformity,wide alveolar and interlabial cleft gaps.Short and obliquely deviated columella**



**Fig 2 A & B:During active naso alveolar molding of the unilateral cleft deformity**



**Fig3 A,B&C:Following nasoalveolar molding;A: Note convexity of alar base,elevation of nasal tip cartilage and proximity of the lip segments at rest.B: Elongation of columella,proximity of alveolar segments C:Nasal symmetry**

The nasal stent and soft denture lining were added to the pre-operative orthopedic plate. Controlled movement of the alveolar segments was obtained by tight positioning of lip segments with a tape combined with the plate. The appliance is worn continuously and removed only for daily cleaning. Parents were instructed on how to tape the lips together and maintain the appliance in place.

The molding plate was modified at weekly intervals to gradually move the alveolar segments and to reduce the cleft gap. This was achieved through the selective grinding of the acrylic from the region into which one

desires the alveolar bone segments to move. At the same time soft denture liner is added to the appliance in the region from where one desires the alveolar bone to be reduced. This procedure is similar to technique described by Grayson et al (1999).<sup>5</sup> The intraoral cleft gap was reduced to 3 mm by gradual activations. The soft denture lining of the appliance achieved the desirable movement of the cleft region.

The correction of nasal cartilage and columella deformity was achieved by adding nasal conformer to the intraoral molding plate.<sup>9,10,11</sup> The nasal conformer is composed of a

0.032 inch diameter stainless steel wire with a hard acrylic resin molding bulb on the top (**Fig.2**). The wire is bent so that the molding bulb is positioned inside the nose underneath the apex of the lower lateral alar cartilage. Parents and caregivers are instructed on how to maintain the appliance in place. Through bi-weekly adjustments to the wire and additions of small amount of hard acrylic resin on the bulb, the columella is gradually elongated. At the same time, tapes-steri strip should be applied to press back on the nasolabial side. When properly taped and adjusted, some temporary blanching of the tissue overlying the tip of the molding bulb can be observed.

At the end of nasopalveolar molding, the columella is lengthened and repositioned from an oblique position into an upright and more midline orientation, which resulted in improved nasal tip projection and alar cartilage symmetry. The contour of the nostril on the cleft side was fashioned to very nearly resemble the nostril on the unaffected side as the alar tissue was molded into a normal convex shape. At the conclusion of nasopalveolar molding the convexity in the alar base, elevation in the nasal tip cartilage and proximity of the lip segments at rest with significant closure of the alveolar cleft gap was noticed.(**Fig-3**)

#### Complications:

Irritation of the cheeks was noticed after the first week due to lip taping, this was overcome by using Comfeel as a base tape applied directly to the skin. The tapes used to apply traction were adhered to these base tapes.

#### CONCLUSION

Nasopalveolar molding has proved to be an effective adjunctive therapy for reducing hard and soft tissue cleft deformity before surgery. However, it is important that parents or caregivers become active members of the treatment team. Similarly, it is crucial that members of the cleft team provide the parents and caregivers adequate training, education, active support and encouragement during nasopalveolar molding treatment. Lack of parent or caregivers' compliance and commitment results in less than ideal clinical outcomes.

#### References

- 1.Cutting CB, Grayson BH, Brech LE, Santiago PE, Wood R, Kwon S. Presurgical columellar elongation and primary retrograde nasal reconstruction in one-stage bilateral cleft lip and nose repair. *Plast Reconstr Surg.* 1998;101: 630 –639.  
[doi:10.1097/00006534-199803000-00009](https://doi.org/10.1097/00006534-199803000-00009)
- 2.Da Silveira AC, Oliveira N, Gonzalez S, Shahani M, Reisberg D, Daw JL, Cohen M. Modified nasal alveolar molding appliance for management of cleft lip defect. *J Craniofac Surg.* 2003;14:700 –703.  
[doi:10.1097/00001665-200309000-00018](https://doi.org/10.1097/00001665-200309000-00018)  
PMid:14501332
- 3.Grayson BH, Cutting CB, Wood R. Preoperative columella lengthening in bi-lateral cleft lip and palate.

*Plast Reconstr Surg.* 1993;92:1422–1423.  
PMid:8248436

4.Grayson BH, Santiago PE. Presurgical orthopedics for cleft lip and palate. In: Aston SJ, Beasley RW, Thorne CHM, eds. *Grabb and Smith's Plastic Surgery*. 5th ed. Philadelphia: Lippincott-Raven; 1997:237–244.

5.Grayson BH, Santiago PE, Brecht LE, Cutting CB. Presurgical nasopalveolar molding in infants with cleft lip and palate. *Cleft Palate Craniofac J.* 1999; 36:486– 498.  
[doi:10.1597/1545-1569\(1999\)036<0486:PNMIW>2.3.CO;2](https://doi.org/10.1597/1545-1569(1999)036<0486:PNMIW>2.3.CO;2)

6.Hardingham TE, Muir H. The specific interaction of hyaluronic acid with cartilage proteoglycans. *Biochim Biophys Acta.* 1972;279:401– 405.  
PMid:4263642

7.Larson M, Sallstrom K, Larson O, McWilliam J, Ideberg M. Morphologic effect of preoperative maxillofacial orthopedics (T-traction) on the maxilla in unilateral cleft lip and palate patients. *Cleft Palate Craniofac J.* 1993;30:29 –34.  
[doi:10.1597/1545-1569\(1993\)030<0029:MEOPMO>2.3.CO;2](https://doi.org/10.1597/1545-1569(1993)030<0029:MEOPMO>2.3.CO;2)

8.Matsuo K, Hirose T, Otagiri T, Norose N. Repair of cleft lip with nonsurgical correction of nasal deformity in the early neonatal period. *Plast Reconstr Surg.* 1989;83:25– 31.  
[doi:10.1097/00006534-198901000-00006](https://doi.org/10.1097/00006534-198901000-00006)

9.McNeil CK. Orthodontic procedures in the treatment of congenital cleft palate. *Dent Rec.* 1950;70:126–132.

10.Nakajima T, Yoshimura Y, Sakakibara A. Augmentation of the nostril splint for retaining the corrected contour of the cleft lip nose. *Plast Reconstr Surg.* 1990;85:182–186.  
[doi:10.1097/00006534-199002000-00003](https://doi.org/10.1097/00006534-199002000-00003)

11.Suri S, Tompson BD. A modified muscle-activated maxillary orthopedic appliance for presurgical nasopalveolar molding in infants with unilateral cleft lip and palate. *Cleft Palate Craniofac J.* 2004;41:225–229.  
[doi:10.1597/02-141.1](https://doi.org/10.1597/02-141.1)  
PMid:15151446

#### Corresponding Author

**Dr. Akshai Shetty KR**

B.D.S.; M.D.S.; M Orth R.C.S.Ed(U.K) FCFD(Taiwan)

Professor

DAPM RV Dental College and Hospital,  
Bangalore, India.

Email: [akshaishetty@gmail.com](mailto:akshaishetty@gmail.com)