

ORTHO – PERIO SYMBIOSIS – A CASE REPORT

¹ Kiran Kumar D¹ Reader, Department of Orthodontics² Ramoji Rao M.V.² Professor and Head, Department of periodontics

^{1,2} Drs. Sudha & Nageswara Rao Siddhartha Institute of Dental Sciences, Chinnaoutpalli, Gannavaram, Vijayawada, Andhra Pradesh– 521286.

ABSTRACT

Although benefits of orthodontic treatment for adult patients were demonstrated as early as the turn of the century, the published statements regarding adult orthodontic treatment were mostly negative. Significant caution and even avoidance of adult orthodontic therapy often were recommended. This article emphasizes the importance of comprehensive treatment of the adult patient with underlying periodontal problems could stop deterioration of the dental general health and helps in the maintenance of success rate in adult orthodontic treatment.

KEY WORDS : Ortho-Perio symbiosis, Adult Periodontics

INTRODUCTION

Patients' perception towards aesthetics and their expectations towards perfection are profound¹. Almost 80% of these adult patients require interdisciplinary treatment planning and treatment execution², even though, patient's chief complaint often is only a tip of the dental iceberg. The other deep rooted problems requires treatment involving many branches of dentistry³. As the demographics of the specialty of orthodontics have changed, the interest of the orthodontic specialist in adult treatment has increased. Many studies confirm the fact that adults as a group are becoming a greater part of the contemporary orthodontic practice⁴⁻⁸. The current period has brought rapid change in cultural environment, greater affluence, sophistication of life style, liberation of the "self" and focus on body image, bringing awareness of the benefit to orthodontics and the teeth as sense organs. Realization that orthodontic treatment enhances self image, social adjustment and removes the stigma of ugliness contributed to establish orthodontics as an important health service that enhances optimal function and well being of a person within his environment⁹.

Case Report:

A 22 year old female patient reported to the orthodontic department with a chief complaint of forward migration and spacing of upper and lower

front teeth, which was increasing gradually since few years. Medical history was insignificant.

Data from records: Preoperative photographs, study models and radiographic records were prepared and the various treatment options were suggested to the patient in the order of preference.

Skeletal evaluation: Lateral cephalogram tracing showed normal maxilla with normal mandible

Dental evaluation: Angle's Class I molar, canine relationship; proclined and crowded upper and lower anterior teeth along with spacing between upper and lower anteriors, the upper lateral incisors extruded beyond the maxillary occlusal plane were clinically found. Generalized gingival recession was also observed along with grade I mobility of upper and lower incisors. Other clinical findings included anterior deep bite with severe anterior tongue thrust.

Soft tissue evaluation: showed convex facial profile with incompetent lips and acute naso-labial angle. There was generalized inflammation of the gingiva.

Radiographic evaluation: Orthopantomograph showed generalized mild bone loss, except in the

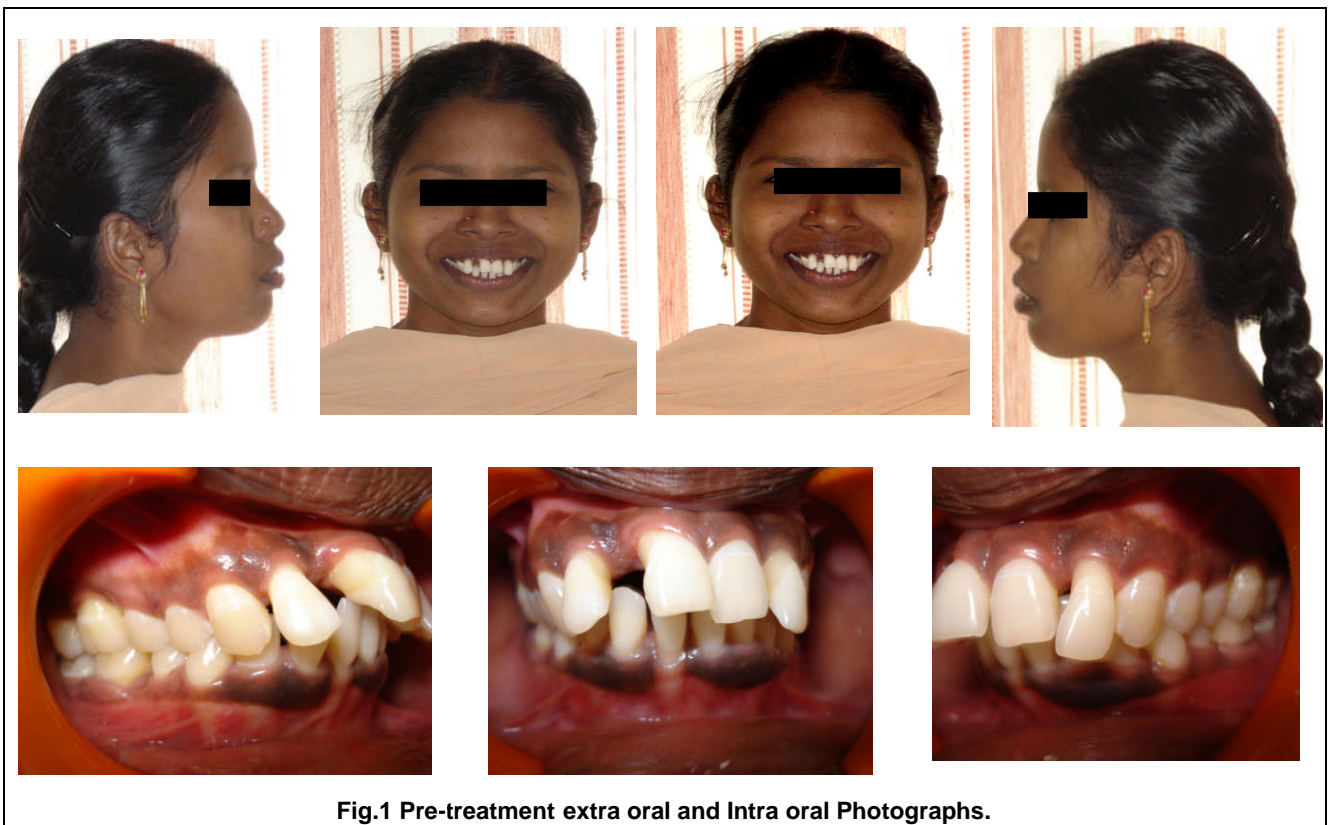


Fig.1 Pre-treatment extra oral and Intra oral Photographs.

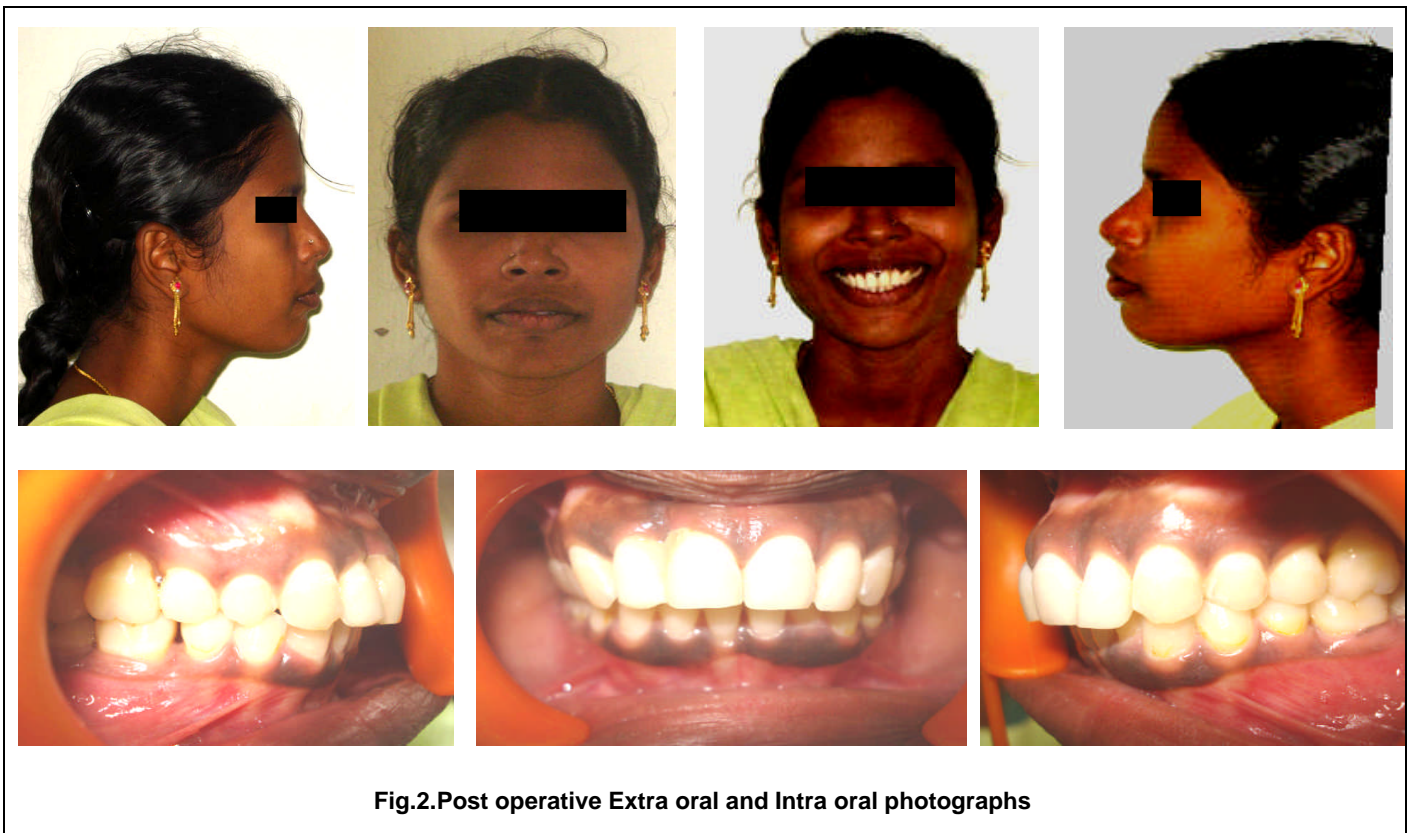

Fig.2.Post operative Extra oral and Intra oral photographs

region of upper and lower anteriors and upper and lower molars where moderate bone loss was observed.

Interdisciplinary Diagnosis and Treatment

Planning: The malocclusion could be a result of combination of dental and periodontal problems associated with anterior tongue thrust habit as shown in the table.

The problem list and discipline involved in treating:

Problem	Discipline
Gingivitis and periodontitis	Periodontics
Dental malocclusion	Orthodontics

Treatment Phases

Pre orthodontic phase: The first phase of treatment always involves a thorough periodontal work-up. Initially the patient was sent to periodontic department for management of generalized periodontitis. Scaling, root planing followed by flap surgery was done.

Orthodontic phase: The orthodontic phase was started after 6 months of periodontal stage which was carried out with 0.022 X 0.028" Pre-adjusted Edgewise fixed Appliance therapy.

Retention phase: Following active orthodontic phase, bonded retainers were fixed in the upper and lower arches from canine to canine, along with Hawley's retainer with tongue guard in the upper arch to stop severe anterior tongue thrust.

Discussion

It is widely believed that an important rationale for performing orthodontic treatment is to promote the health of the periodontium, thereby enhancing longevity of the dentition. It is therefore assumed that adults with untreated malocclusion would be subject to a greater prevalence of periodontal disease than if their malocclusion had been

corrected orthodontically. The relationship between malocclusion and periodontal disease has received much attention in the literature, with little support for such a relationship^{10,11}.

With effective plaque and disease control, teeth with reduced periodontal support can undergo successful tooth movement without further compromising their periodontal health. Treatment undertaken in the presence of inflammatory disease can accelerate attachment loss and predisposes to acute inflammatory episodes. During treatment it is essential that oral hygiene maintenance is excellent.

Orthodontics is not and should not be restricted only to children. A malocclusion remains one, whether it is in child or in an adult. The primary goal of orthodontics is to improve the dental occlusion and to remove malocclusion as an aetiological factor of periodontal disease. Aesthetic improvement enhances an individual sense of self and it most gratifying. Attachment loss can result in pathologic tooth migration when the soft tissues are unfavourable and occlusal loads are high¹². Hence, interdisciplinary treatment is a must to achieve optimum function, health and esthetic results.

CONCLUSION:

There are many benefits of integrating orthodontics and periodontics in the management of patient with underlying periodontal defects. The treatment of adult patients is often just one component of a more complex treatment involving several disciplines. Not all periodontal problems are treated in the same way, but comprehensive management of adult patients with both periodontal and orthodontic problems have been shown to improve the condition of periodontium and re-establish a healthy and well functioning long lasting dentition, if oral hygiene is maintained. In some instances the orthodontist acts as a co ordinate when inter disciplinary treatment is required.

References:

1. Birte Melsen, Sonil Kalia Inter disciplinary approaches to adult Orthodontic care, Journal of Orthodontics, 2001;28 :191-96
2. Akin-nergiz, N,Nergiz, I. and Schmage,p Inter disciplinary concepts in treating adult patients, Journal of orofacial Orthopaedics (Munich), 1997; 58:340-51.
3. Kuseler, A. and Melsen, B Orthodontic treatment: artor science? Journal of clinical Orthodontics, 2000; 6: 371-75

4. Williams RL, Shilliday DJ, Kress W, et al. The American Association of Orthodontists study of the availability of orthodontic services. AM J ORTHOD,1975;68:326-38.
5. Gottlieb EL, Vogels DS. 1983 JCO orthodontic practice study. Part I. Trends. J Clin Orthod 1984;18:167-73.
6. Gottlieb EL, Vogels DS. 1983 JCO orthodontic practice study. Part II. Practice success. J Clin Orthod 1984;18:247-53.
7. Gottlieb EL, Nelson AH, Vogels DS. JCO orthodontic practice study, part 2: practice success. J Clin Orthod 1989;23:677-85.
8. McLain JB, Proffit WR. Oral health statistics in the United States: prevalence of malocclusion. J Dent Educ 1985;49: 386-96.
9. Coenraad F.A.Moorrees: Heritage paper, Reflections on an academic career in teaching and research, AJO 1993; 516-522.
10. Lusteran, E. A.: Clinical significance of periodontic orthodontic interrelationships, N. Y. State Dent. J,1974;40:147-156.
11. Kessler, M.: Interrelationships between orthodontic and periodontics, AM. J. ORTHOD,1976;70:154-177,

Corresponding Author

Dr. D. Kiran Kumar MDS

Reader

Department of Orthodontics

Drs. Sudha & Nageswara Rao Siddhartha Institute of

Dental Sciences

Chinnaoutpalli,

Gannavaram – 521286,

Andhrapradesh.

Ph.No. +919848021426, Fax No. 08676-257368,

sidsprincipal@yahoo.co.in