

Oral Rehabilitation of Non-Syndromic Oligodontia; a Case Report

Manoranjan Mahakur*

Department of Pedodontics and Preventive Dentistry, SCB Dental College and Hospital, Cuttack, Odisha, India

ABSTRACT

Absence of teeth is common in human dentition and it may be seen in primary or permanent dentition with unknown etiology but may be hereditary. According to the number of teeth, absent is can be divided into hypodontia or oligodontia. The prevalence rate may be from 1.6-6.9%. Sometime it may be associated with some syndrome or without any syndrome. This case presented with retained deciduous teeth and spacing in a 11 year's male child without any other organ disorders. The retention was due to the absence of a permanent successor. So oral rehabilitation was done in the patients by considering the growth development and parent consent.

Keywords: Missing dentition; Hypodontia; oligodontia; Syndrome

INTRODUCTION

The most prevalent dentofacial malformation in humans is hypodontia with a prevalence of 1.6-6.9%. The term hypodontia refers to the absence of Six or less number of teeth whereas oligodontia refers absent of more than six teeth and anodontia for complete missing of teeth [1,2].

Many theories suggest the multiplicity of tooth agenesis as a multifactorial etiology that involves genetic regulation and environmental factors so it mostly occur as part of a recognized genetic syndrome or as a non-syndromic isolated trait [3,4].

Tooth agenesis is considered rare in the deciduous dentition and more predilected towards girls. The most commonly missing teeth are the mandibular second premolars followed by the maxillary second premolar and maxillary lateral incisors and the rarely missing teeth are the maxillary central incisors, maxillary and mandibular first molars and canines [5].

Hypodontia leads to delayed development and lack of growth of alveolar bone resulting in facial appearance of an edentulous person with mandibular protrusion and lip eversion on occlusion [6-8].

The objective of this paper is to show the clinical case of a child with the absence of 7 permanent teeth, of idiopathic etiology, without a history of hypodontia in the family and its rehabilitation [9,10].

CASE REPORT

A male patient of 11 years reported to the department of pediatric and preventive dentistry, SCB dental college and hospital Cuttack with his mother's. The mother having complained of non-shedding of deciduous teeth of the upper anterior, the patients had no history of trauma or extractions. There was no history of craniofacial clefts in maternal the paternal family of the child. The pregnancy of the mother was uneventful. The boy was the first child and only child but family history revealed that father was having missing lower right lateral incisor with any extraction history (Figure 1). The extraoral examination of the face mimics that of the edentulous person, with a mandibular protrusion, maxillary retrusion and deep sulcus (Figure 2). The Physical examination of the patients revealed no abnormality in either hairs or nails. The boy was having a good body built and normal perspiration so suggestive of non-syndromic [11-14].

On intraoral examination the following teeth were present clinically 16, 15, 14, 53, 52, 51, 26, 25, 24, 63, 62, 21, 37, 36, 75, 34, 33, 32, 31, 47, 46, 85, 44, 43, 42, 41 (Figures 3 and 4). Presence of high frenal attachment with diastema, high and narrow palatal arch, No caries tooth found, oral mucosa and gingiva are good. To rule out other suspecting abnormalities or associated syndrome OPG, Lateral cephalometry and some blood test advised. The panoramic radiograph showed absence of 11, 12, 13, 22, 23, 35, 45, permanent teeth and submerged 85 (Figure 5). The blood report

*Correspondence to: Manoranjan Mahakur, Department of Pedodontics and Preventive Dentistry, SCB Dental College and Hospital, Cuttack, Odisha, India; Tel: 9439755811; E-mail: drmanakumar@gamil.com

Received: 17-Jun-2021, Manuscript No. AEDJ-22-10732; Editor assigned: 21-Jun-2021, PreQC No. AEDJ-22-10732 (PQ); Reviewed: 14-Oct-2021, QC No. AEDJ-22-10732; Revised: 10-Mar-2023, Manuscript No. AEDJ-22-10732 (R); Published: 17-Mar-2023, DOI: 10.35248/0976-156X.23.15.245

Citation: Mahakur M (2023) Oral Rehabilitation of Non-Syndromic Oligodontia; a Case Report. Ann Essence Dent. 15:245.

Copyright: © 2023 Mahakur M. This is an open-access article distributed under the terms of the Creative Commons Attribution License, which permits unrestricted use, distribution, and reproduction in any medium, provided the original author and source are credited.

of serum calcium, alkaline phosphate, T3, T4, TSH was on the normal range.

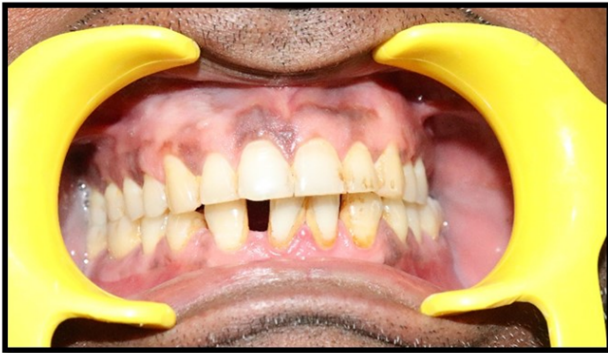

Figure 1: Missing lower right lateral incisor.

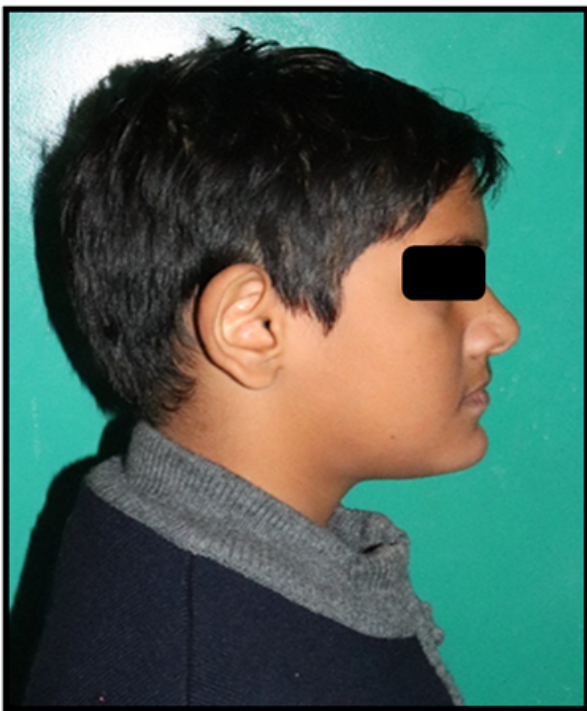

Figure 2: Extraoral examination of the face mimics that of the edentulous person, with a mandibular protrusion, maxillary retrusion and deep sulcus.

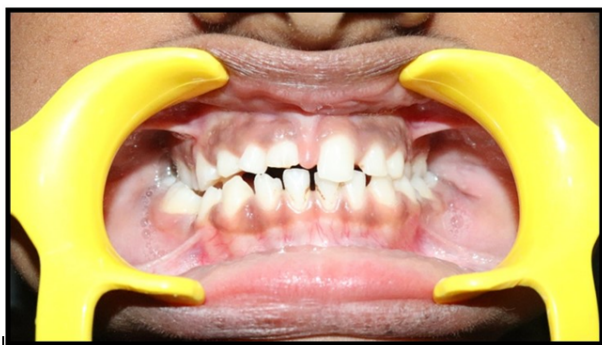

Figure 3: Intraoral examination of teeth.

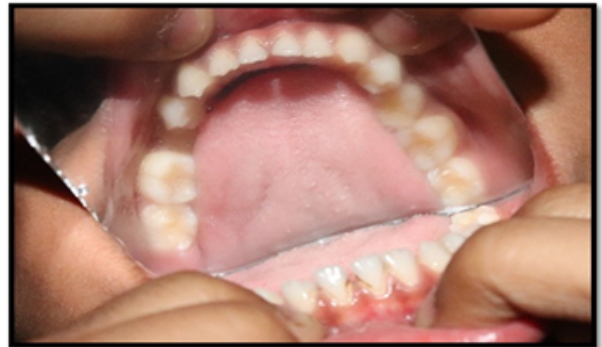
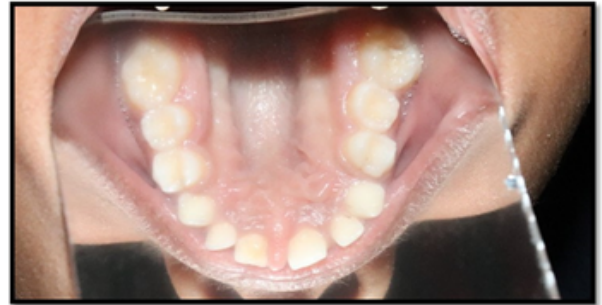
Figure 4: Intraoral examination inner view.

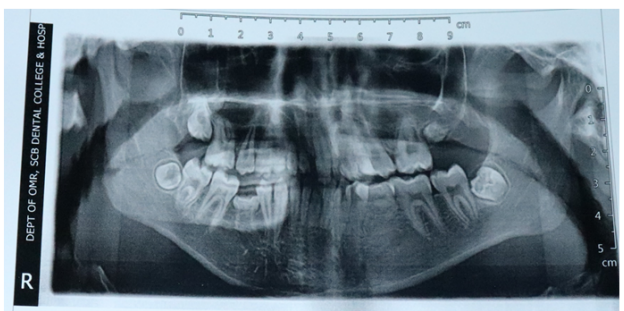


Figure 5: The panoramic radiograph showed absence of 11, 12, 13, 22, 23, 35, 45, permanent teeth and submerged 85.

TREATMENT

Laser frenectomy was performed for high frenal attachment under all precautions. The retained deciduous teeth 51 and 52 was not mobile so it restored with the composite build up and planned for implant prosthesis in the future after completion of growth (Figures 6 and 7).

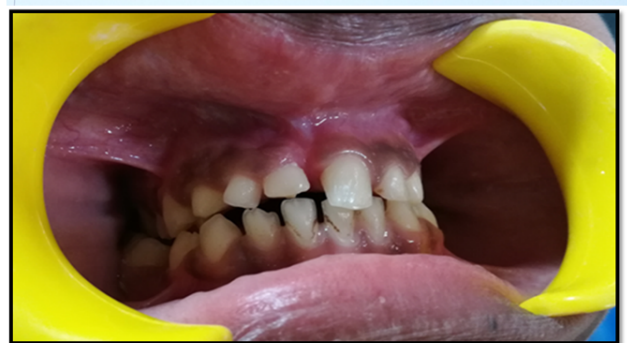

Figure 6: The retained deciduous teeth 51 and 52.

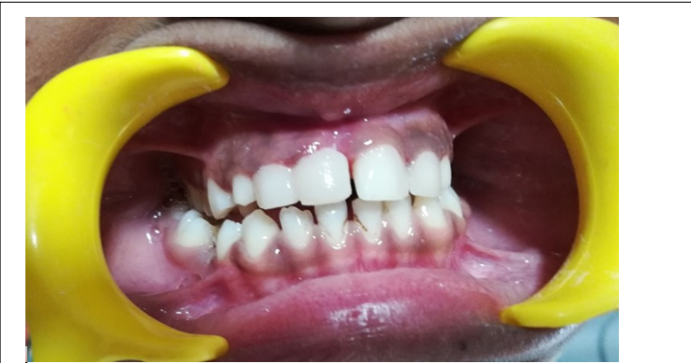

Figure 7: It restored with the composite build up and planned for implant prosthesis in the future after completion of growth.

DISCUSSION

Many genetic syndromes are associated with oligodontia such as ectodermal dysplasia, incontinentia pigmenti, down syndrome, rieger syndrome, wolf-hirschhorn syndrome, van der woude syndrome, ectrodactyly-ectodermal dysplasia-clefting syndrome, cleft lip palate ectodermal dysplasia syndrome, oral-facial digital syndrome type I, witkop tooth-nail syndrome and Fried syndrome. In this case report, oligodontia is not associated with any syndrome, which is a rare finding. Oligodontia is often related to conical shaped teeth, microdontia, delayed eruption of permanent teeth, and increased freeway space, and retention of deciduous teeth. Our case report also had retention of deciduous teeth. The etiology of congenital absence of permanent teeth is due to the failure of the lingual or distal proliferation of the tooth bud cells from the dental lamina and also due to multiple genetic and environmental factors. The environmental factors such as irradiation, tumors, trauma, hormonal influences, rubella, and thalidomide may contribute to the cause of oligodontia with some hereditary genetic dominant factors, or to both [11]. The mutations of PAX9 and MSX1 genes identified to have been associated with a non-syndromic form of tooth agenesis. Tsai, et al. have reported a case of oligodontia in a 6-year-old girl with congenital absence of 16 permanent teeth [13]. Rasmussen P reported non-syndromic 9 cases with the absence of 14-24 teeth excluding the third molar [15,16].

The present report shows congenitally missing 7 permanent teeth in the 11 year-old boy. But no identifiable etiology was found. The patient was young and growing, so the extraction of deciduous teeth with the placement of implants was postponed till growth completion and treated conservatively.

CONCLUSION

Patients with features of oligodontia or hypodontia or anodontia should be evaluated thoroughly and genetic

counselling should be carried out to rule out the presence of any syndromes and early management. The patient presenting with missing teeth suffers not only from masticatory and esthetics problems but psychological stress as well, as it can lower the self-esteem of an otherwise healthy individual so a through treatment planning should be done with multidisciplinary approach. Treatment should start as early as possible to prevent the late consequence and patients' growth status should be considered.

REFERENCES

1. Pannu P, Galhotra V, Alhuwalai P, Gambhir RS. Non-syndromic oligodontia in permanent dentition: a case report. *Ghana med J*. 2014;48(3):173-6.
2. Bural C, Oztas E, Ozturk S, Bayraktar G. Multidisciplinary treatment of non-syndromic oligodontia. *Eur j dentistry*. 2012;6(02):218-26.
3. Tangade P, Batra M. Non syndromic oligodontia: Case report. *Eth j health sci*. 2012;22(3).
4. Biradar V, Biradar S. Non-syndromic oligodontia: Report of two cases and literature review. *Int J Oral Maxi Pathol*. 2012;3(4):48-52.
5. Kotsiomiti E, Kassa D, Kapari D. Oligodontia and associated characteristics: assessment in view of prosthodontic rehabilitation. *Eur J Prosthodont Restor Dent*. 2007;15(2):55-60.
6. Rathee M, Mahesh G, Arun K, Richa M, Renu K. Rehabilitation of non-syndromic oligodontia of primary and permanent dentition in young patient-A rare case report. *J Interdiscipl Med Dent Sci*. 2014;2(117):2.
7. Nagaraj T, Kongbrailatpam S, Mohiyuddin YS, Doye I. Non-syndromic oligodontia: A case report.
8. Nagaveni NB, Umashankara KV, Radhika NB, Satisha TS. Non-syndromic oligodontia report of a clinical case with 14 missing teeth. *Bangladesh J Med Sci*. 2011;10(3):200-2.
9. Rengasamy S, Nambirajan N, Vidyashree Nandini V. MINIMALLY INVASIVE MANAGEMENT OF NON-SYNDROMIC OLIGODONTIA IN AN ADULT-A CASE REPORT. VOLUME 1 ISSUE 3. 2017 Jun:31.
10. Chou MY, Prostho C. Non-Syndromic Oligodontia: A Case Report.
11. Hiremath MC, Srinath SK, Sushma HS. Non-Syndromic Oligodontia: A Case Report. *RGUHS J Dent Sci*. 2021;13(3).
12. Rathore R, Deepshika R, Piyush A, Don V, Sumita K. A non-syndromic hereditary oligodontia-a rare case report. *J Oral Med Oral Surg Oral Pathol Oral Radiol*. 2016;2:180-3.
13. Attavar RK. A Multidisciplinary Full Mouth Rehabilitation Of Non-Syndromic Oligodontia Using Twin Stage Hobo's Technique-A Case Report. *Int J Clin Dent Sci*. 2017;7(1).
14. Zameer M, Dawood T, Basheer SN, Peeran DS, Peeran SA, Birajdar SB. Non-Syndromic Oligodontia In A Child-A Rare Case. *Int J Dentistry Oral Sci*. 2021;8(1):1057-9.
15. Wira VV, Himawan LS, Odang RW, Masulili C, Nelwan LC. Rehabilitation of Non-Syndromic Oligodontia on Young Adult: Case Report. *ii Proceeding Book*.:291.
16. Tomo S, Simonato LE. Non-Syndromic Oligodontia: A Case Report. *Int J Oral Maxi Pathol*. 2014;5(3).