

NON-SURGICAL ENDODONTIC MANAGEMENT OF THE COMBINED ENDO-PERIO LESION: REPORT OF THREE CASES

¹ Rahul Kumar	¹ Post Graduate Student
² Suvarna Patil	² Professor And Head
³ Upendra Hoshing	³ Professor
⁴ Ashish Medha	⁴ Professor
⁵ Anil Munavalli	⁵ Senior Lecturer
⁶ Sharnappa Kambale	⁶ Senior Lecturer
⁷ Rushikesh Mahaparale	⁷ Post Graduate Student

¹⁻⁷ Department Of Conservative Dentistry and Endodontics, Vasantdada Patil Dental College and Hospital Maharashtra, India

ABSTRACT:

Endodontic–periodontal lesions offer a constant challenge to the clinician for diagnosis, treatment and prognosis of the teeth that are of great concern. Treatment and prognosis of endodontic–periodontal diseases vary depending on the cause and the correct diagnosis of each specific condition. This article presents successful healing of combined endo-perio lesions after non-surgical endodontic management with long term follow up.

KEYWORDS: Non-surgical Endodontic treatment , Combined Endo-Perio Lesion, Pulp Necrosis, Periapical Abscess, Secondary Periodontitis.

INTRODUCTION

The pulp and the periodontium are closely related as they are ectomesenchymal in origin ¹, and pathways of communications between these structures often determine the process of disease in these tissues. The main pathways for communication between the pulp and periodontium are (1) dentinal tubules, (2) lateral and accessory canals, (3) apical foramen, thereby creating the endo-perio lesion².

Pulp tissue succumbs or degenerates due to a number of reasons such as caries, restorative procedures, restorative materials (iatrogenic), chemical insult, thermal insult, trauma and periodontal disease. When products of pulp degeneration reach the supporting periodontium, rapid inflammatory responses like bone loss, tooth mobility, sinus tract formation, apical periodontitis, periradicular lesions, retrograde periodontitis and reverse pocket formation may occur². The periodontal disease progression is much slower and has a gradual effect. It is characterized by presence of localized inflammation or tissue infarction, a decrease in the number of cells, bone resorption, fibrosis and coagulation necrosis³.

Proper endodontic procedures and techniques are the key factors for treatment success of endo-perio lesion. When assessing the retention rate of endodontically

treated teeth, it has been found that nonsurgical endodontic treatment is a predictable procedure with excellent long-term prognosis^{4, 5}. It is imperative to completely clean, shape and obturate the canal system well in order to enhance successful outcomes⁶.

Periodontal health should be reassessed only after one to two months ⁷ since aggressive removal of periodontal ligament and underlying cementum during interim endodontic therapy adversely affects periodontal healing⁸.

In our patients, diagnosis of the etiology of the pathosis was more difficult since there were extensive deep probing depths in more than one site. However, successful healing was obtained after thorough disinfection and sealing of the root canals.

Case Report -1

A 35 year old female patient reported to the Department of Conservative Dentistry and Endodontics, Vasantdada Patil Dental College and Hospital, Sangli, with the chief complaint of mild pain and swelling on right back region of the jaw. The medical history was non contributory. Intra oral examination revealed deep mesio-occlusal carious lesion with mandibular right first molar and disto-occlusal

carious lesion with mandibular right second premolar. Probing depth observed was 7mm mesial to tooth # 30 with grade II furcation involvement. Palpation revealed tenderness on percussion and grade I mobility.

Pre treatment examination (IOPA radiograph and pulp vitality test) suggested combined endo- perio lesion of non vital mandibular right first molar. Radiographic examination demonstrated severe bone loss around the mesial portion of distal root, interradicular area and the apex of mesial root of mandibular right first molar (Fig.1A). Initially root canal therapy followed by periodontal regenerative surgery was suggested.

The tooth was isolated under rubber dam (Hygienic Dental Dam, Coltène Whaledent, Germany). Adequate

endodontic access cavity was prepared after excavation of caries and working length radiograph was taken after initial identification of three canals with # 15 K-files (Kerr Manufacturing Co., Romulus, MI) (Fig.1B). Cleaning and shaping of the root canal was performed by using stainless steel file with a crown-down technique under copious irrigation with saline, 5% sodium hypochlorite solution(Dentpro,Chandigarh,India) and 17% EDTA (Glyde File Prep,Dentsply,France). All canals were dried and an interappointment dressing with calcium hydroxide was placed and a temporary filling was placed in the access cavity. Patient was kept on medication.

Three weeks later, the tooth was asymptomatic and soft tissues looked normal. After rubber dam isolation, the calcium hydroxide was removed from the canals using EDTA and sodium hypochlorite 5.25%. Master cone radiograph was taken. The canals were finally rinsed with normal saline, dried with absorbent points (Dentsply Maillefer) and obturation was performed using cold lateral compaction of gutta-percha (Dentsply Maillefer) using AH Plus resin sealer (Maillefer, Dentsply, Konstanz, Germany) (Fig.1C). An IRM (Dentsply) temporary restoration was placed in the access cavity and patient was recalled after one week for periodontal regenerative procedure.

Despite numerous reminders, the patient did not return for reassessment. After three months, patient returned. At this visit tooth was asymptomatic and there was no permanent restoration in the tooth. The probing depths were 3mm all around the tooth and no inflammation were seen on soft tissues. Radiographic examination revealed evidence of regeneration of the periradicular bone (Fig.1D). Thus it was decided that the patient should be followed up before undergoing periodontal surgery. At this time, IRM was removed and cavity was restored with silver amalgam restoration. (Dispersalloy, Denstply). The patient returned one year after the placement of the permanent restoration and tooth was asymptomatic, probing depths were still 3mm all around the tooth and soft tissues appeared free of inflammation (Fig.1E). Radiographic examination revealed dramatic regeneration of the periradicular tissues. The tooth was symptom-free since completion of the root canal; hence, it was decided to restore the tooth with full coverage metal crown (Fig.1F).

Case Report -2

A 53 year old male patient reported to the Department of Conservative Dentistry and Endodontics, Vasantdada Patil Dental College and Hospital, Sangli, with the chief complaint of pain in the right back region of lower jaw. The patient was diabetic and was under medication. Intra oral examination revealed occlusal carious lesion with mandibular right first molar , tenderness on percussion and deep periodontal pocket with probing depth of 13 mm was associated tooth with grade II furcation involvement.

Pre treatment examination (IOPA radiograph and pulp vitality test) suggested combined endo- perio lesion of non vital mandibular right first molar. IOPA radiograph showed

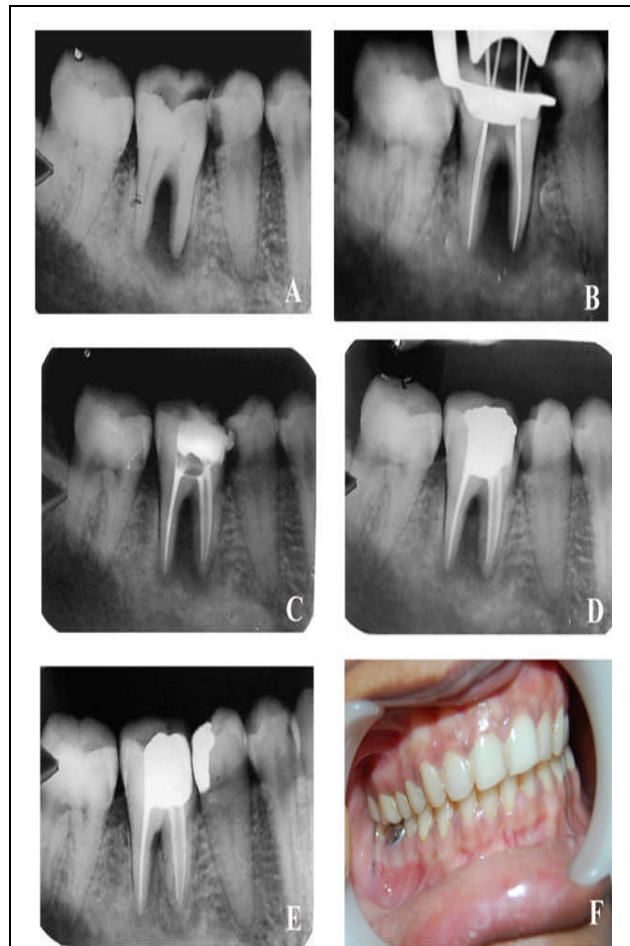


Fig.1.(A) Preoperative radiograph showing showed severe bone loss around the mesial portion of distal root, interradicular area and the apex of mesial root of tooth #30. (B) Working length radiograph of tooth #30 (C) Radiograph taken upon completion of root canal treatment. (D)Three month follow up showing periradicular tissues showed sign of regeneration (E) One year follow up radiograph showing evidence of bony healing (F) Clinically, no inflammation was seen on soft tissues and the tooth restored with full coverage metal crown.

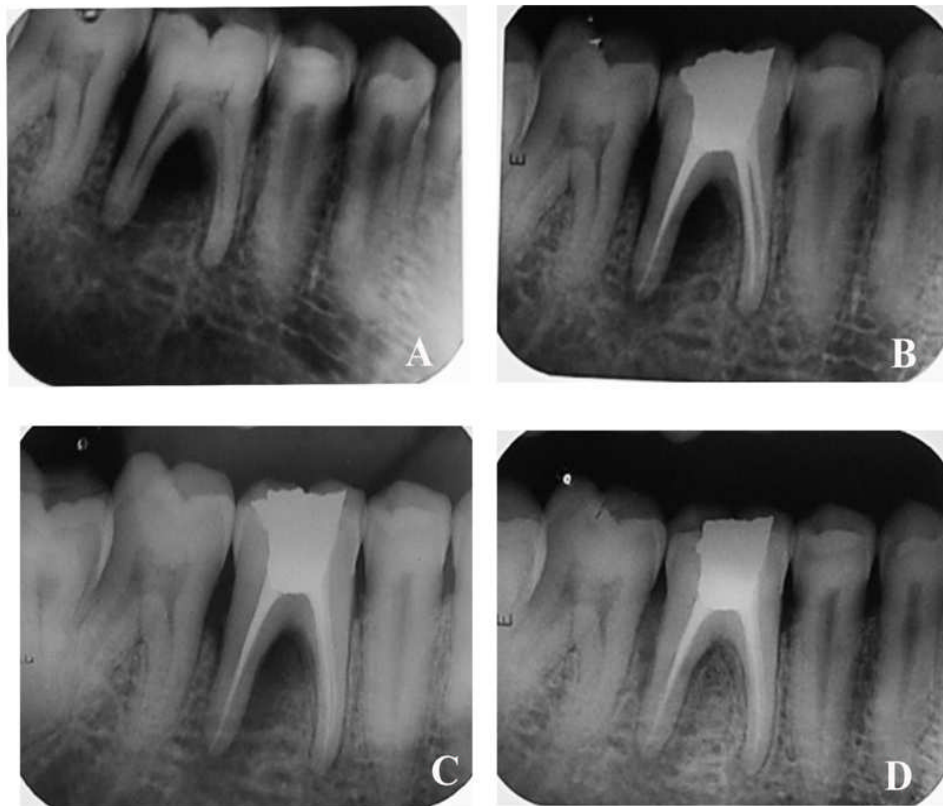


Fig. 2 (A) Preoperative radiograph showing showed bone loss around the distal root, and interradicular area of tooth #30. (B) Radiograph taken upon completion of root canal treatment. (C) three month follow up showing periradicular tissues showed sign of regeneration (D) One year follow up radiograph showing evidence of bony healing.

bone loss around the distal root, and interradicular area of mandibular right first molar (**Fig.2A**). Scaling and polishing followed by root canal treatment was suggested. As the patient was diabetic the periodontal surgery was postponed. Through scaling and polishing was done. The root canal treatment was completed as described in case one and the patient were kept under follow-up (**Fig.2B**).

Tooth was asymptomatic, when patient returned after three months, periradicular tissues showed sign of regeneration and probing depth was 6 mm (**Fig.2C**). Follow up examination after one year showed probing depth was 3 mm all around the tooth and evidence of regeneration of periradicular tissue on radiographic examination (**Fig.2D**).

Case Report -3

A 14 year old female reported to the Department of Conservative Dentistry and Endodontics, Vasantdada Patil Dental College and Hospital, Sangli, with the chief complaint of deep occlusal caries and intraoral swelling associated with mandibular left first molar. The tooth was tender on percussion and pus discharge was seen from gingival sulcus after probing. A probing depth was 12 mm was present.

Pre treatment examination suggested combined endo-perio lesion of non vital mandibular left first molar. IOPA radiographic showed bone loss all around the root, and interradicular area (**Fig.3A**). Scaling and polishing followed by root canal treatment and further periodontal surgery was suggested.

The root canal treatment was completed as described in case one and the patient were kept under follow-up (**Fig. 3B**). The 3 month follow-up showed the tooth was asymptomatic. A 12 month follow-up examination showed dramatic regeneration of periradicular tissues(**Fig.3C**) and 18 month follow up revealed that patient was asymptomatic since completion of root canal treatment and complete regeneration of periradicular bone(**Fig.3D**).

Discussion

Endodontic-periodontal lesion is a clinical manifestation of the pathologic/inflammatory intercommunication between pulpal and periodontal tissues. On the basis of the pathologic origin, Simon et al⁹ classified endodontic-periodontal lesions into primary endodontic lesions, primary endodontic lesions with secondary periodontic involvement, primary periodontic lesions, primary periodontic lesions with secondary

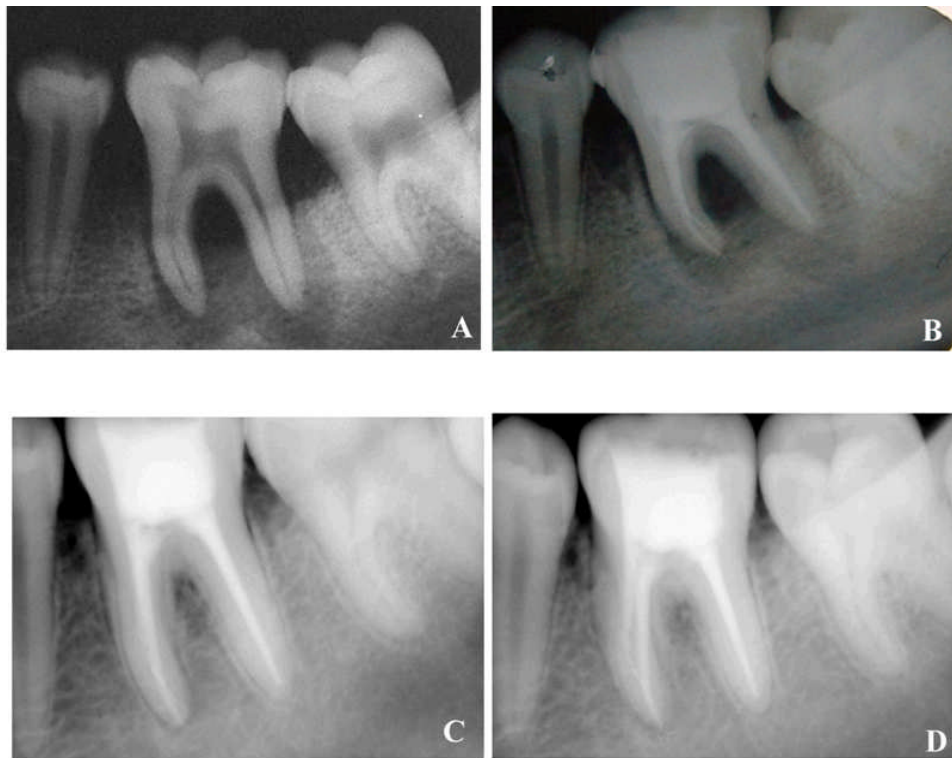

Fig.3 (A) Preoperative radiograph of tooth #19 extensive periradicular bone loss. (B) Radiograph taken upon completion of root canal treatment. (C) One year follow up radiograph showing evidence of bony healing (D) One year and six months follow-up X-ray film showing considerable bone apposition, probing depths were of no more than 3mm all around the tooth.

endodontic involvement, or true combined lesions. Later, an additional classification was added by Belk and Gutmen as concomitant endodontic and periodontal lesions¹⁰. Formulating a differential diagnosis among combined lesions has always been challenging because most often clinicians do not have a complete history of the course of disease progression.

Endodontic-periodontal combined lesion is a true challenge. Its management requires thorough understanding of wound healing process involving both endodontic and periodontal complex. The treatment of endodontic-periodontal combined lesions requires both endodontic therapy and periodontal regenerative procedure. The success rate of the endodontic-periodontal combined lesion without a concomitant regenerative procedure has been reported to range from 27%–37%^{11,12}.

For accurate diagnosis and treatment planning, the clinician should be able to differentiate between endodontic and periodontal lesions. The main factors taken into consideration are pulp vitality and type and extent of the periodontal condition. In addition, a negative response to thermal stimuli and lack of mobility of the tooth may indicate that the lesion is purely of endodontic origin. In such cases root canal therapy should be performed and periodontal therapy avoided, or at least delayed, until one or two months after the root canal has

been performed⁸. Periodontal therapy is then performed only if the attachment apparatus does not seem to be improving. Follow-up examination is crucial when attempting to evaluate the prognosis of the treated tooth.

Analyzing a series of retrospective studies, Blomlof et al⁸ concluded that endodontic infection promotes periodontal pocket formation and should be regarded as a risk factor in periodontitis progression. Therefore, a primary endodontic lesion draining through the attachment apparatus should be treated initially by endodontic therapy¹³. Root canal disinfection is crucial when attempting to achieve regeneration of the periradicular tissues^{14,15,16}. In fact, there is evidence that proper root canal treatment can heal sinus tracts originating from an endodontic lesion even if they have been present for a long time¹⁷.

In this case series, there were deep probing depth along more than one surface of the tooth. Radiographically there was extensive bone loss around the root and interradicular area, however successful disinfection and filling of the root canal system of teeth led to regeneration of the attachment apparatus without further periodontal therapy. In our cases, calcium hydroxide was used as the intracanal inter-appointment dressing to disinfect the root canal system further and to evaluate the improvement of the surrounding tissues at the second appointment, at

which time it was decided to fill both teeth. Complete healing of periradicular bone was seen after one year. After long term follow-up radiographs showing complete healing of periradicular tissues around the root in all three cases was seen.

CONCLUSION

This case report demonstrated that endodontic lesions with involvement of the attachment apparatus can be successfully healed by performing adequate root canal treatment with great emphasis on disinfection of the root canal system. Teeth that appear to have a periodontal problem of endodontic origin have an excellent prognosis but it depends on the extent of the periodontal disease and assessment of the therapeutic prognosis, presence or absence of periapical radiolucency, tooth mobility, properly performed root canal treatment, and appropriate healing time.

References

1. Walker M. The pathogenesis and treatment of endo-perio lesions. *Pathogenesis* 2001; 2(3):91-5.
2. Ingle JI. *Endodontics* Philadelphia 2008. 6th edition;p25
3. Cohen Pathways Of The Pulp 9th edition;pp243
4. Lazarski MP, Walker WA, Flores CM, Schindler WG, Hargreaves KM. Epidemiological evaluation of the outcomes of nonsurgical root canal treatment in a large cohort of insured dental patients. *J Endod* 2001; 27: 791-796
5. Rotstein I, Salehrabi R, Forrest JL. Endodontic treatment outcome: survey of oral health care professionals. *J Endod* 2006; 32:399-403.
6. Rotstein I, Simon J. The endo-perio lesion: a critical appraisal of the disease condition. *Endodontic Topics* 2006; 13(1):34. <http://dx.doi.org/10.1111/j.1601-1546.2006.00211.x>
7. Paul B, Hutter, JW The endodontic-periodontal continuum revisited: new insights into etiology, diagnosis and treatment. *AJAD* 1997 128: 1541-48.
8. Blomlof LB Relationship between. periapical and periodontal status. *J Clin periodontol* 1993 20: 117-23. PMID:8436630 <http://dx.doi.org/10.1111/j.1600-051X.1993.tb00325.x>
9. Simon JH, Glick DH, Frank AL. The relationship of endodontic-periodontic lesions. *J Periodontol* 1972; 43:202-8.
10. Belk, C.E., and Gutman, J.L. *J. Can. Dent. Assoc.*, 1990.56:1013
11. Hirsch JM, Ahlstrom U, Henrikson PA, Heyden G, Peterson LE. Periapical surgery. *Int J Oral Surg* 1979; 8:173-85.
12. Skoglund A, Persson G. A follow-up study of apicoectomized teeth with total loss of the buccal bone plate. *Oral Surg Oral Med Oral Pathol* 1985; 59:78-81.
13. Zehnder M, Hasselgren G Pathologic interactions in pulpal and periodontal tissues. *J Clin periodontal* 2002 29: 663-71.
14. Bystrom A, Sundqvist G Bacteriologic evaluation of the effect of 0.5% sodium hypochlorite in endodontic therapy. *Oral Surg Oral Med Oral Pathol* 1983 55: 307-12. [http://dx.doi.org/10.1016/0030-4220\(83\)90333-X](http://dx.doi.org/10.1016/0030-4220(83)90333-X)
15. Bystrom A, Claesson R, Sundqvist G The antibacterial effect of camphorated paramonochlorophenol, camphorated phenol and calcium hydroxide in the treatment of infected root canals. *Endo and Traum* 1985 1: 170-175.
16. Trope M, Delano O, Orstavik D Endodontic treatment of teeth with apical periodontitis: Single vs. multi-visit treatment. *J Endod* 1999 25: 345-350. [http://dx.doi.org/10.1016/S0099-2399\(06\)81169-6](http://dx.doi.org/10.1016/S0099-2399(06)81169-6)
17. Stromberg R, Hasselgren G, Bergsted H (1972) Endodontic treatment of resorptive periapical osteitis with fistula. A clinical and roentgenological follow-up study. *swedish Dent J* 1972 65: 457-465

Corresponding Author

Dr. Rahul Kumar

Department Of Conservative Dentistry and Endodontics
 Vasantdada Patil Dental College & Hospital
 A/P Kavalapur, Tal- Miraj, Dist- Sangli, Maharashtra, India 416306
Contact No.: +91-9372180472
E- mail: dr.rahul1982@gmail.com