

## LINGUAL ORTHODONTICS

|                                      |                                   |
|--------------------------------------|-----------------------------------|
| <sup>1</sup> Praveen chirivella      | <sup>1</sup> Postgraduate student |
| <sup>2</sup> Gowri Sankar Singaraju  | <sup>2</sup> Professor            |
| <sup>3</sup> Prasad Mandava          | <sup>3</sup> Professor and Head   |
| <sup>4</sup> Vivek Reddy Ganugapanta | <sup>4</sup> Senior Lecturer      |

<sup>1-3</sup> Department of Orthodontics, Narayana Dental College, Nellore, Andhra Pradesh, India.

**ABSTRACT:** With the invention of lingual orthodontics, the patients received the most aesthetic orthodontic treatment, which attracted many orthodontists and patients to seek this aesthetic treatment. Lingual orthodontics is one of the fixed orthodontic technique in which brackets are invisible. The use of invisible orthodontic technique increased the patient's self-esteem, but there exists a difference in bonding technique, biomechanical aspect and the anchorage considerations between the conventional and lingual orthodontic techniques. In this article, the complete lingual orthodontic technique has been reviewed.

**KEYWORDS:** Aesthetic, Biomechanical, Lingual, Orthodontics, Technique.

## INTRODUCTION

Most patients seek orthodontic treatment for esthetic purposes.<sup>1</sup> As the number of adult patients seeking orthodontic treatment is increasing, it is well known that adults have a negative reaction toward the esthetics of conventional fixed orthodontic appliances and do not want them to show. Even though brackets made of plastic and porcelain coated archwires have appeared in the market, the only solution that provides the ultimate in esthetics during the treatment is to attach the appliances to the lingual surfaces of the teeth<sup>2</sup>.

*Development of Lingual Appliance*

In 1726, Pierre Fauchard suggested the possibility of using appliances on the lingual surfaces of teeth. In 1841, Pierre Joachim Lefoulon designed the first lingual arch for expansion and alignment of the teeth. The lingual appliance was started in Japan by Kinja Fujita (1970s) to satisfy the orthodontic needs of patients who practiced martial arts, to protect the soft tissues (lips and cheeks) from the possible impact against brackets. Fujita was the first to develop the lingual multibracket technique using the mushroom shaped arch wire. Later, Craven Kurz and these two engineers Craig Andreiko and Frank Miller developed the first generation of the Kurz lingual bracket. To test and continue their research in this field, Ormco founded a Task Force comprising Craven Kurz, Jack Gorman (Marion, IN), Bob Smith (Stanford, FL), "Wick" Alexander and "Moody" Alexander (Dallas, TX), James Hilgers (Mission Viejo, CA) and Bob Scholz (Alameda, CA), and administrators Floyd Pickrel, Ernie Strauch, and Michael Swartz. They developed Kurz lingual bracket from first to seventh generation. Kurz also developed numerous pliers and instruments for the clinical practice of lingual orthodontics<sup>3</sup>.

In the United States, pioneers in this field were Kelly (1982), who used Unitek labial brackets (3M Unitek, 2724 South Peck Road, Monrovia, CA 91016) on the lingual surfaces, and Paige (1982), who used Begg light wire brackets on the lingual surfaces. Creekmore (1989) developed a complete technique with vertical slot lingual brackets, together with a laboratory system (The Slot Machine). Following this initial development and expansion of lingual orthodontics in the 1990s, interest, particularly in the United States, decreased, probably due to the poor standard of completed cases. In 1996, Craven Kurz, William Laughlin, Thomas Creekmore, Jim Wildman, Giuseppe Scuzzo, Didier Fillion, and Pablo Echarri together with other clinicians founded the Lingual Study Group, in Denver, Colorado, with the aim of relaunching lingual orthodontics, especially in the United States. The American Lingual Orthodontics Association (ALOA), founded in 1987. Didier Fillion has stimulated and been involved in the establishment of many lingual scientific societies, such as the European Society of Lingual Orthodontics (ESLO), Societe Francaise d Orthodontie Linguale (SFOL), British Society of Lingual Orthodontics (BLOS), and most recently the World Society of Lingual Orthodontics (WSLO). Furthermore, together with Alain Decker and Gerard Altounian he established one of the first university lingual orthodontics programs at Paris V University.

The effort of several dedicated clinicians, many of the issues responsible for this decline have been overcome. The development of indirect bonding permitted more precise lingual bracket positioning and reduced the chair side time and labor required for bonding procedures. The next technological advance was the customization of lingual brackets with composite, which compensated for the gaps between standardized bracket bases and the

variable morphology of the lingual tooth surfaces. This allowed the laboratory to incorporate much of the biomechanical plan into the brackets and their positioning, thus reducing the need for wire bending<sup>4</sup>. We are now in a period of resurgence, the technique has become more sophisticated, the clinical results achieved can stand on an equal footing with the best of conventional labial techniques, and the acceptance of technique by the profession is growing rapidly<sup>3</sup>.

#### **Patient Selection and Diagnostic Considerations**

Most malocclusions that can be treated by conventional labial techniques can also be treated with lingual orthodontic techniques; however, not all patients can be treated with lingual orthodontics, particularly in patients with expected low discomfort tolerance.

#### **Favorable Cases<sup>5</sup>**

- Cases with mild incisor crowding and with anterior deep bite
- Long and uniform lingual tooth surfaces without fillings, crowns, or bridges
- Good gingival and periodontal health
- Keen, compliant patient
- Skeletal Class I pattern
- Mesocephalic or mild/moderate brachycephalic skeletal pattern
- Patients who are able to adequately open their mouths and extend their neck

#### **Unfavorable Cases<sup>5</sup>**

- Dolichocephalic skeletal pattern
- Maximum anchorage cases, unless treated with micro implants
- Short, abraded, and irregular lingual tooth surfaces
- Presence of multiple crowns, bridges, and large restorations
- Patients with a low level of compliance
- Patients with limited ability to open the mouth (trismus)
- Patients with cervical ankylosis or other neck injuries that prevent neck extension

#### **Diagnostic considerations in lingual orthodontics:<sup>5</sup>**

Diagnosis is an important issue for all orthodontic treatment techniques and even more so in lingual orthodontics.

##### **1. Lingual crown height:**

Lingual crown heights are usually 30% shorter than their labial surfaces. The most suitable teeth for lingual orthodontics are those with long and smooth

surfaces with at least 7mm of lingual crown height of incisors and incisors with lingual surfaces shorter than 7 mm should be reconstructed.

##### **2. Periodontal and gingival considerations:**

Before starting active orthodontic treatment, the patient should have a healthy periodontium and should be able to maintain a high level of oral hygiene.

##### **3. Restorative considerations:**

- The likelihood of encountering more extensive restorative and prosthetic work is naturally increased in the adult patient. Many of the adult cases presenting for lingual orthodontics have mutilated malocclusions, and treatment planning for these cases, particularly when using the lingual technique, requires special consideration.

- The presence of crowns, bridges, and large restorations impact negatively on achieving good adhesion and these needs to be treated with special bonding techniques for plastic, metallic, or porcelain surfaces.

##### **4. Surgical Cases:**

- With these cases, the best possible presurgical tooth position should be achieved to minimize the postsurgical orthodontic treatment time.
- The patient must be consulted on the possibility of bonding labial brackets just before surgery to assist with the postsurgical fixation.

##### **5. Preprosthetic Cases:**

Lingual orthodontic treatment is often indicated in patients requiring preprosthetic tooth movement.

#### **Lingual orthodontics Vs Buccal orthodontics**

The mechanotherapy involved in lingual orthodontics is altered in some respects, because of the difference in the position of the brackets<sup>6</sup>. For the patient, lingual appliances have several clear-cut advantages over labial appliances:<sup>7</sup>

1. Facial surfaces of the teeth are not damaged from bonding, debonding, adhesive removal or decalcification from plaque retained around labial appliances.
2. Facial gingival tissues are not adversely affected.
3. The position of the teeth can be more precisely seen when brackets and archwires do not obstruct their surfaces.

4. Facial contours are truly visualized since the contour and drape of the lips are not distorted by protruding labial appliances.
5. Most adult and many young patients would prefer "invisible" lingual appliances if costs, treatment times, and results were comparable to those of labial appliance treatment.

Given these advantages for patients, the perfection of lingual treatment seems worthwhile. An acceptable lingual orthodontic appliance system must include the following key elements:

1. A mechanical appliance that aligns teeth from the lingual aspect as efficiently as a labial appliance.
2. A means of positioning brackets precisely to create a near straight wire appliance on the lingual aspect.
3. A consistent and accurate indirect bonding technique.
4. A selection of preformed archwires complete with canine – premolar offsets
5. Specially designed pliers with longer handles and offset beaks.
6. Lingual bracket removing pliers
7. Offset torquing keys
8. Training for the orthodontist and staff to develop their lingual treatment technique so that it becomes routine to the labial treatment.

#### Biomechanical differences between labial and lingual appliances are <sup>6</sup>

- The overall ratio of anterior lingual distance to labial interbracket distance was calculated to be 1:1.47.
- In vertical direction applying an intrusive force in labial orthodontics on a tooth that is initially positioned between retroclination of 20° and proclination of 45° will create a lingual root movement (proclination). In lingual orthodontics, labial root moment (retroclination) will occur when the tooth is retroclined more than 20°.
- In sagittal direction, both systems the direction of force applied passes relatively far from the Cr in both systems, and therefore a moment is created. The moment tends to move the crown in the force direction and the apex in the opposite direction. In this sense, there is no difference between lingual and labial orthodontics.
- In transverse direction in both systems, the vectors of force are passing similarly relative to the Cr, and hence produce similar moments: the moment tends to create a movement of the crown in the force direction and a root movement in the opposite direction. Clinically, it seems that expansion is easier in lingual than in labial orthodontics.

- Class II division 1 malocclusion is treated with lingual orthodontics, the anterior biteplane make the expansion of the upper dentition easier. The vertical opening and the clockwise rotation of the mandible caused by lingual orthodontics induces a Class II tendency.
- In class II division 2 the upper incisors are retroclined, the vector of the anterior intrusive force can pass palatally to the CR and hence worsen the retroclination.

#### Lingual Appliances

##### Bracket Systems<sup>8</sup>

During the past 20 years, various lingual brackets have been designed and modified for patient control, mechanical efficiency and precise tooth positioning (**Fig.1 to Fig.11**). They are:

- Conceal
- Fujita Lingual Bracket
- STb (SCUZZO- TAKEMOTO bracket)
- Forestadent
- Stealth Brackets
- Philippe Self Ligating Lingual Brackets
- Kelly Bracket
- Kurz Lingual Brackets
- Adenta Brackets
- In- Ovation- L Bracket
- lbraces

#### Lingual Orthodontic bracket progressive development from generation 1 to 7: <sup>9</sup>

Craven Kurz and two engineers Craig Andreiko and Frank Miller developed the first generation of the Kurz lingual bracket. <sup>5</sup>

##### Generation #1—1976

The first Kurz Lingual Appliance was manufactured by Ormco. This appliance had a flat maxillary occlusal bite plane from canine to canine. The lower incisor and premolar brackets were low profile and half-round, and there were no hooks on any brackets.

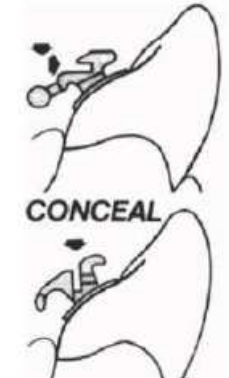
##### Generation #2—1980

Hooks were added to all canine brackets.










##### Generation #3—1981

Hooks were added to all anterior and premolar brackets. The first molar had a bracket with an internal hook. The second molar had a terminal sheath without a hook button a terminal recess for elastic traction.


**DIFFERENT LINGUAL BRACKET SYSTEMS**




**Fig.1. CONCEAL System**

|                  | Facial view   | Lateral view  | Occlusal view   |
|------------------|---|---|---|
| Anterior bracket |  |  |  |
| Premolar bracket |  |  |  |
| Molar bracket    |  |  |  |


**Fig.2. Fujita Lingual Bracket**




**Fig.3. STb (SCUZZO-TAKEMOTO) bracket**




**Fig.4. Forestadent**




**Fig.5. Stealth brackets**




**Fig.6. Philippe Self Ligating Brackets**




**Fig.7. Kelly brackets**




**Fig.8. Kurz Lingual Brackets**



**Fig.9. Adenta brackets**



**Fig.10. In- Ovation-L Bracket**



**Fig.11. Ibraces**

(courtesy:Adarsh R, Prabhakar R, Karthikeyan M K, Yugandhar G. Indirect bonding with various bracket systems inlingual orthodontics. Ann Dent 2012; 4: 92-98.)

**Generation #4—1982–84**

This generation saw the addition of a low profile anterior inclined plane on the central and lateral incisor brackets. Hooks were optional, based upon individual treatment needs and hygiene concerns.

**Generation #5—1985–86**

The anterior inclined plane became more pronounced, with an increase in labial torque in the maxillary anterior region. The canine also had an inclined plane; however, it was bi beveled to allow intercuspation of the maxillary cusp with the embrasure between the mandibular canine and the first premolar. Hooks were optional. A transpalatal bar attachment was now available for the first molar bracket.

**Generation #6—1987–90**

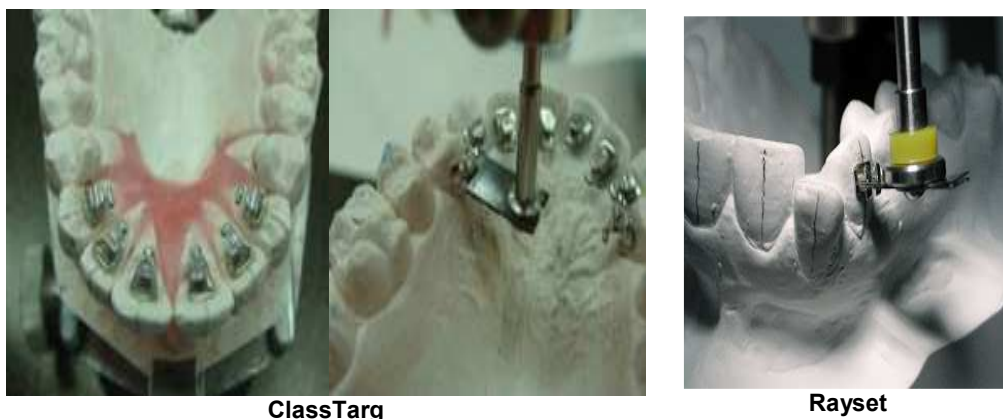The inclined plane on the maxillary anteriors becomes squarer in shape. Hooks on the anteriors and premolars were elongated. Hooks were now available for all the brackets. The transpalatal bar attachment for the first molar band was optional. A hinge cap, allowing ease of archwire manipulation, was now available for molar brackets.

**Generation #7—1990**

The maxillary anterior inclined plane is now heart-shaped with short hooks. The lower anterior brackets have a larger inclined plane with short hooks. All hooks have a greater recess/access for ligation. The premolar brackets were widened mesiodistally and the hooks were shortened. The increased width of the premolar bracket allows better angulation and rotation control. The molar brackets now come with either a hinge cap or a terminal sheath.

**Laboratory procedures used in Lingual orthodontics**

1. **Materials used for attaching brackets to the working models:**<sup>10</sup>
  - Softened sugar daddy candy
  - Sticky wax
  - Water soluble adhesive
  - Adhesive coated brackets
  - Soluble water-paper paste
  - Composite adhesives (CLASS)
  - Macrofilled resin (BEST AND TARG)
  - Bonding paste
2. **Bracket positioners:**<sup>10</sup>
  - Individual bracket placement indicators (1982 Myrberg)
  - Individual preformed height gauges (Reichheld)
  - Customized lingual appliance setup service (CLASS) system
  - Toque angulated device (TARG) system
  - Equal specific thickness (BEST) system
  - KIS bracket positioner
  - Mushroom bracket positioner
  - Brackets positioned using ideal archwire (HIRO) system
  - Bracket positioning using Tip, torque, angulation (Ray set) system
  - Slot machine (Creekmore)
  - Lingual bracket jig
  - German Transfer Optimized Positioning (TOP) system
  - Computer driven system (Sure smile)
  - CAD-CAM (Ortho CAD, Lingual care) system



**Fig.12.Different lingual bracket positioners**



### 3. Materials used for making Transfer trays: <sup>10</sup>

- Vacuum formed clear placement trays
- Impression compound (Memosil)
- Optosil transfer trays
- Xantopren transfer trays
- Dual clear tray systems (Inner softer and outer harder trays)
- Clear acrylic transfer trays
- Silicone transfer trays – low, medium and high viscosity
- Polyvinyl siloxane transfer trays
- Hot glue guns
- Transfer wires
- Resin core transfer trays (Dura lay)

### 4. Full arch transfer trays: <sup>11</sup>

- Opaque silicone trays (Xantopren, Optosil)
- Translucent silicone trays (Memosil)
- Thermoplastic trays (Copyplast, Bioplast)

### 5. Single tooth transfer system: <sup>11</sup>

- The Hiro System
- Kyung's Individual Indirect Bonding Trays
- Kim's Convertible Resin Core (CRC) Ready-Made Transfer Tray

### 6. Materials used for bonding brackets: <sup>10</sup>

- Chemically cured
  - Composites (Thomas)
  - No mix adhesive (Fried and Neumann, 1983)
  - Resin-reinforced glass ionomers
  - Acrylated epoxy adhesives
  - Cyanoacrylates
  - BIS-GMA based adhesives
- Light cured
  - Visible light cured adhesives
  - Light cured lightly filled sealant
  - Filled flowable composite
  - Fiber reinforced composite
- Thermally cured
- Dual cure adhesives (cement setting / light activated) – Glass Ionomer components + Resins<sup>12</sup>
- Tri-cured adhesives (chemical / light activated and cement setting reaction) – Glass Ionomer components + Resins<sup>12</sup>

### Anchorage consideration in Lingual orthodontics

In lingual as well as labial orthodontics, maintaining anchorage during treatment can be challenging. Anchorage provision and control is a key requirement for the successful treatment of most malocclusions irrespective of the treatment technique. When using the lingual technique, specific problems relating to the provision of adequate anchorage may be attributed to a number of factors.<sup>13</sup>

### Anchorage Assessment in the Sagittal Plane: <sup>14</sup>

Posterior teeth may need to be limited in their mesial movement, maintained in position, or even distalized to allow proper positioning of the anterior segments. Posterior anchorage control is normally more difficult in the upper arch than in the lower for these reasons:

1. The upper anterior teeth are larger.
2. The upper anterior brackets have substantially more built in tip.
3. The upper incisors require more torque control and bodily movement than the lower incisors, which require only distal tipping or uprighting.
4. The upper molars usually move mesially more readily than the lower molars do.
5. There are more Class II cases, requiring greater anchorage control in the upper arch, than Class III cases.

### Anchorage Assessment in the Vertical Plane:

#### Vertical Control of Incisors

Preadjusted appliances tend to produce a transitional deepening of the anterior overbite during leveling and aligning, primarily due to the tip in the canine brackets. As the archwire passes through this bracket, it tends to lie incisal to the incisor bracket slots. When the wire is engaged in the incisor brackets, it causes extrusion.

This effect can be avoided either by not bracketing the incisors at first or by not tying the archwire into the incisor brackets, allowing it instead to lie incisal to the brackets until the canine roots have been uprighted and moved distally, under control of the lacebacks.

#### Vertical Control of Molars

In highangle cases, the upper second molars are usually not banded or bracketed at first to minimize extrusion. If they must be banded, archwire steps should be placed behind the first molars to avoid their extrusion. If the upper first molars require expansion, an effort should be made to achieve bodily movement rather than tipping, which extrudes the palatal cusps. This is best accomplished with a fixed expander and a combi or a highpull headgear. Cervical pull Headgear should not be used in highangle cases.

If a palatal bar is used, it should lie approximately 2mm away from the roof of the palate so that the tongue can exert an intrusive force on the molars. In some cases, an upper or lower posterior bite plate is useful in minimizing extrusion of the molars.

#### **Anchorage Assessment in the Lateral Plane:**

No special care is needed to maintain lateral anchorage control in most patients. With certain malocclusions, however, the following points should be observed. Upper and lower intercanine width should be kept as close to the starting dimensions as possible to ensure stability. Crowding should not be relieved by uncontrolled expansion of the upper and lower arches.

#### **Six keys for anchorage:**

In view of the anchorage requirements for this procedure, the "six keys for anchorage control in lingual sliding mechanics" have been suggested as a means of providing maximum anchorage control<sup>15</sup>

1. Standard lingual- bracket-jig prescription in the anterior segment, with slight extra torque and no extra tip for extraction treatment, and posteriorly, mesial off-center position and mesial angulation of the molar brackets.
2. Bi dimensional approach, with its inherent feature of less friction during sliding mechanics.
3. Posterior bite stops for bite opening.
4. Light orthodontic forces for space closure, with Class I (elastomeric chain), class II or class III (elastic) mechanics.
5. Inclusion of second molars in the anchorage unit.
6. Placement of an exaggerated or reversed curve of Spee, in the maxillary and mandibular space closing archwire respectively.

#### **Lingual straight wire appliance ( Fig.13)**

The lingual orthodontic technique of Fujita uses a mushroom arch form because of the morphology of the lingual tooth surfaces. Takemoto and scuzzo found, that by cutting the clinical crowns off a plaster cast, the buccolingual distances at the gingival margin did not vary substantially. This led us to conclude that straight archwires could be used in lingual orthodontics if they were placed as close to gingival margin as possible.<sup>16</sup>

#### **Lingual straight bracket design:**

The following factors were incorporated in lingual straight brackets

1. Wire in anterior segment must be positioned more lingually.
2. Wire in anterior segment must be positioned more gingivally.

3. Buccolingually thickness increases in premolar region

#### **Conventional lingual bracket versus lingual straight bracket:**

1. The bracket stem of lingual straight bracket is positioned more gingivally relative to bonding base.
2. Bracket stem of lingual straight bracket is longer labiolingually.
3. Lingual straight bracket is shorter vertically.
4. Compared to commercially available lingual brackets, arch wire insertion is in the opposite direction, from the top instead of from the bottom.

#### **The new bracket offers the following advantages:**

1. Flossing is easier because the arch wire is farther from the lingual surface and incisal edge and hygiene is not difficult at the gingival margins, due to the lack of hooks and severe undercuts.
2. So interdental stripping can be performed during treatment without removing the archwire.
3. Bracket thickness is virtually same but the mesiodistal width is much smaller, allowing adequate interbracket distances.
4. Less composite is needed on the mandibular molars to raise the bite, since the brackets are placed more gingivally.
5. Rotations can be more easily accomplished because the arch wire can be tied tightly to the bottom of the bracket slots also, rotations can be more easily corrected because the force is applied over a wider span.
6. Expansion in an anterior direction is more effective because the most labially positioned tooth is ligated first. The ties are secure enough that the arch wire.
7. Torque control is improved; the reverse slot direction ensures that the archwire seats fully in the bracket slot.

The new STb design eliminates the need for inset bends between the canines and first premolars, simplifying sliding mechanics and making leveling and alignment more effective. Brackets with gingival hooks are available easily tied with metal or elastomeric ligatures, reducing chair time compared with conventional lingual appliances.

#### **Orapix system:<sup>18</sup>**

Fillion developed an alternative straight wire technique, using the Orapix digital system to fabricate lingual appliances from a virtual setup. **(Fig.14)**

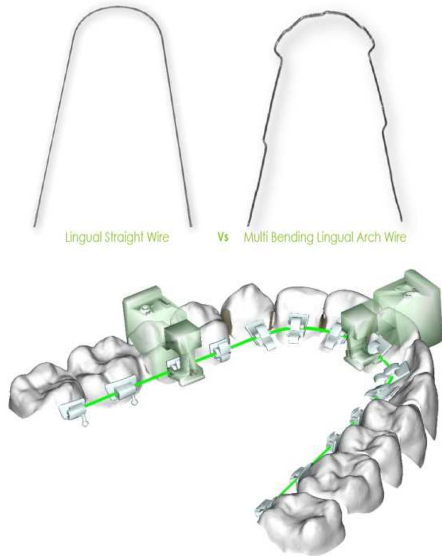


Fig.13.Lingual straight wire appliance

**Lingual light-wire techniques**

In 1982, Paige<sup>19</sup> described a lingual light-wire technique using Unipoint combination brackets with slots oriented in the occlusal-incisal direction and with vertical slots for use of auxiliaries and horizontal slots in unraveling of crowding incisors. There is a gingival ‘wing’ to place elastic modules on continuous elastic chains. The problem of short interbracket distance was partially overcome. Using this technique, the lingual tooth contours are much less a variable factor because torque control can be achieved by properly shaped torquing auxiliaries and placement of brackets is sensitive only to the incisal-lingual placement. Therefore, indirect bonding is not required.

**Lingual orthodontics: The future**

The future of lingual orthodontics is dependent on the following three factors<sup>20</sup>

1. Technology
  - a. Appliance design and manufacture
  - b. Laboratory protocols
2. Demography
  - a. Falling birth rates
  - b. Increasing aging populations
3. Attitude changes in public and professional

**Appliance design and manufacture:**

Orthodontists have been well served by the Ormco Generation 7 during almost two decades; but today a series of new bracket designs are appearing, all with the same aims of greater efficiency and comfort for the patient.

**Scuzzo Takemoto Bracket (STb) Appliance:**

This recently introduced smaller, more comfortable bracketed appliance still requires indirect bracket placement in the manner developed over the past two decades. The STb appliance maximizes the interbracket distance and uses very light forces to create very rapid initial alignment following past tried and proved principles contributing to excellent results in comparatively short treatment times. (Fig.15)

It has been suggested that for certain non-extraction malocclusions, the STb appliance may be easily set up on the malocclusion model without a sophisticated laboratory set-up procedure. Assuming that the bracket slot-height is correct, the treatment may be completed with round wires only. Such a treatment protocol would reduce laboratory procedures, resulting in lower laboratory fees, and therefore lessen the cost to the patient. In an extraction treatment program, the use of a more sophisticated diagnostic set-up is to be recommended.

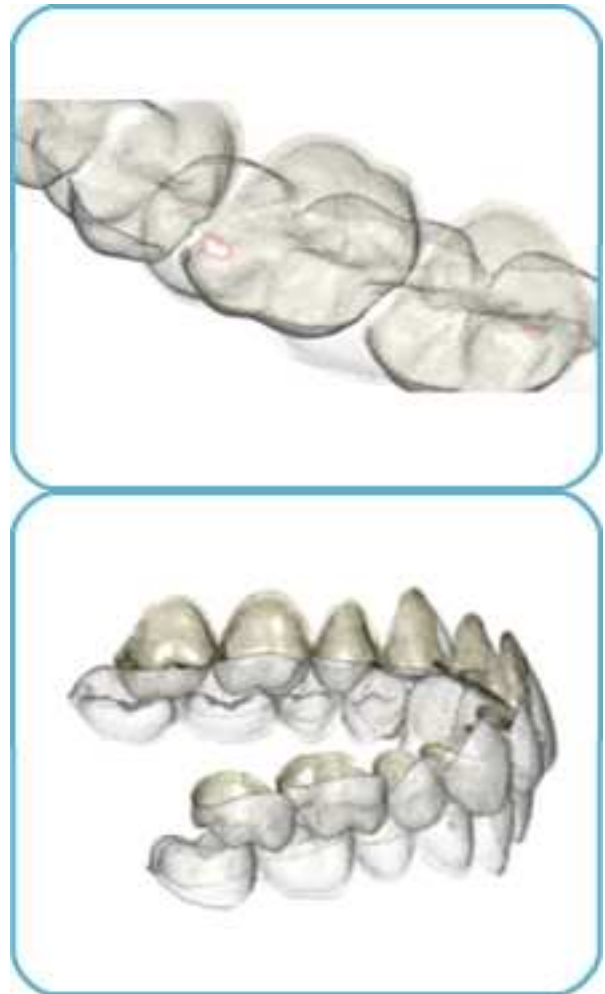


Fig.14. Orapix system – Virtual imaging





Fig.15.ScuzzoTakemoto bracket

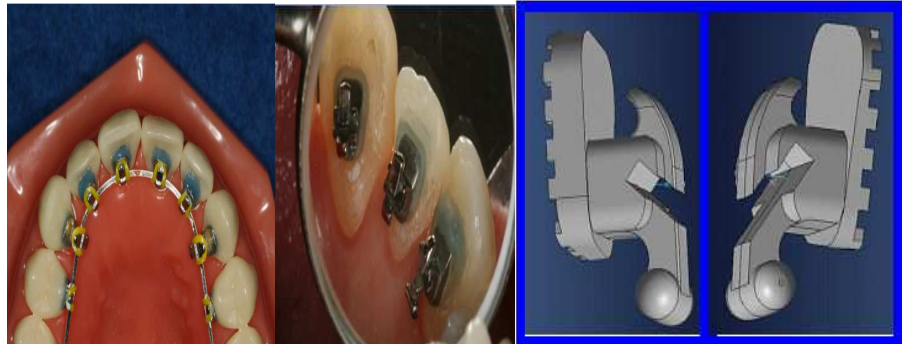


Fig.16. Prieto Straight Wire bracket(PSWb)

**Prieto Straight Wire bracket (PSWb):<sup>21</sup>**

The third-generation PSWb thus offers mechanical advantages over both alternative lingual appliances i.e, PSWb-1 and PSWb-2. Furthermore, the PSWb system simplifies bracket placement and permits fast, precise indirect bonding with reduced chair time, at a lower cost to the patient (Fig.16)

**Evolution Lingual Technique Appliance:**

Self-ligating brackets have a great appeal; but to be successful as a lingual bracket, they must have a robust, durable opening or closing mechanism. In a malocclusion with crowded lower incisors, the bracket width encroaches on the inter bracket space to the extent that the physical diameter of the arch wire, even with nickel-titanium wires, may prevent closure of the bracket's mechanism thus reducing initial efficiency.

**Invisalign:**

While not a lingual orthodontic appliance, Invisalign it is an esthetic appliance, which has highlighted the public perception of esthetic orthodontics with a well conducted and funded public relations campaign.

**Lingual Care Bracket System:<sup>22</sup>**

It uses computer-aided design / computer- aided manufacturing (CAD/CAM) software Custom fabrication of the Lingual care brackets guarantees an exact fit with an extremely low profile, providing absolute control over bodily tooth movements. Modular construction allows the individual components of the system base, bracket, and hook to be positioned independently. The three-dimensional slot precision achieved during the manufacturing process results in minimal archwire play, allowing immediate insertion of a full-size, computer-designed archwire. Patient comfort is improved by a low-profile, form-fitting appliance; speech is less affected, and

the tongue less irritated. The gold alloy also offers an alternative to patients with nickel allergies.

**Incognito Appliance:**

This computer-generated appliance uses three dimensional computer scanning to ensure efficiency of tooth movement by designing brackets and bonding pads specifically for each individual tooth with the bracket slot in the most advantageous position on the lingual surface of the dentition. (Fig.17)

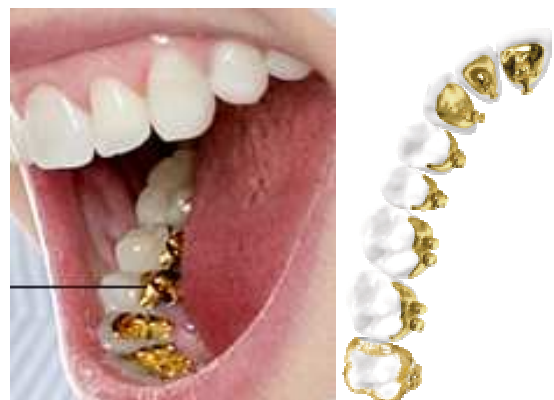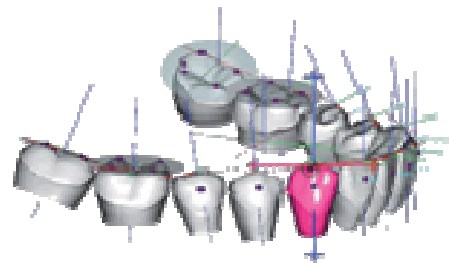


Fig.17.Incognito appliance

**Computer-Aided Design of a Lingual Orthodontic Appliance Using Cone-Beam Computed Tomography:**  
23

This method uses CAD/CAM software and 3D printing to produce a customized positioner for each tooth, thus ensuring accurate bonding. The acrylic positioners can be saved so that brackets can be properly resealed in the event of bond failures. Although CBCT is not as precise in measuring dental morphology as surface-scanning methods, which reach an accuracy of 1 micron, it is now accurate to a minimum voxel size of 80 microns, and research has confirmed a 1:1 image to reality ratio. The manufacturing of customized lingual brackets and positioners can be easily applied in the office to make customized lingual orthodontic appliances more acceptable to both patients and orthodontists. (Fig.18)

**LAMDA (Lingual Archwire Manufacturing and Design Aid):**<sup>24</sup>

The LAMDA wire-bending robot is much simpler than the robots used in commercially outsourced systems, since it manufactures only 1st-order bends. Although this requires the use of the Hiro bracket positioning system for 2nd- and 3rd-order bends, a series of archwires is created by a wire-bending robot to achieve the orthodontist's treatment goals; bending archwires by hand would be difficult and reduce the efficiency of this appliance. The computer-generated appliances are expensive to the orthodontist and therefore a cost that must be eventually borne by the patient. The orthodontist is able to regulate the process at any time with more flexibility than in outsourced systems. ( Fig.19)

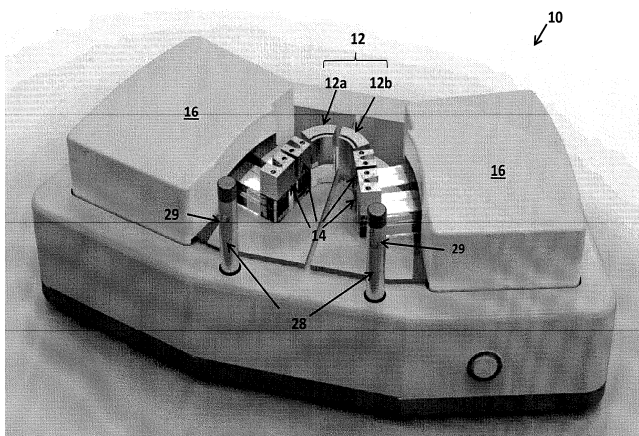


**Fig.18.CAD CAM Technique.**

**Laboratory Protocols:**

Computer technology has developed to allow extremely accurate 3D scanning, software for the creation of a virtual model, bracket placement, and the construction of transfer trays .This protocol allows the orthodontist the opportunity to adjust on the computer screen in virtual dimension the final tooth position before bracket placement and tray construction. The virtual images used in the consulting office are also an excellent patient encouragement and education instrument.<sup>25</sup>

A second, technological advance is the bracket positioning robot, which uses sophisticated 3D scanning devices to create a virtual dentition onto which any bracket can be placed with a high degree of accuracy. Transfer trays are then fabricated for bonding brackets to the dental surfaces. Such technology eliminates many of the possible inaccuracies that could occur with the creation of an ideal diagnostic set-up on a plaster model. The bracket placement robot that presently exists for labial bracket placement is currently being trialed with lingual bracket placement.



**Fig.19. LAMDA wire bending robot**  
<http://www.google.com/patents/US20110314891>

**References:**

1. Zange SE, Ramos AL, Cuoghi OA, Mendonca MR, Suguino R. Perceptions of laypersons and orthodontists regarding the buccal corridor in long- and short-face individuals. *Angle Orthod*. 2011;81:86–90.
2. Caniklioglu C, Ozturk Y. Patient Discomfort: A Comparison between Lingual and Labial Fixed Appliances. *Angle Orthod* 2004; 75: 86–91.
3. Echarri P. Revisiting the history of Lingual orthodontics: A Basis for the future. *Semin Orthod* 2006; 12: 153-59.
4. Mujagic M, Fauquet C. Digital Design and Manufacturing of the Lingual care Bracket System. *J clin Orthod* 2005; 39: 375-82.
5. Echarri P. Lingual Orthodontics: Patient Selection and Diagnostic Considerations. *Semin Orthod* 2006; 12: 160-66.
6. Goren S, Zoizner R, Geron S, Romano R. Lingual orthodontics (LO) versus buccal orthodontics (BO): biomechanical and clinical aspects. *J Ling Orthod* 2002; 3: 1-7.
7. Canikligou C, Yildiz O. Guray bite raiser: its clinical use in lingual orthodontic treatment. *J Ling Orthod* 2000; 2: 71-77.
8. Adarsh R, Prabhakar R, Karthikeyan M K, Yugandhar G. Indirect bonding with various bracket systems inlingual orthodontics. *Ann Dent* 2012; 4: 92-98.
9. R. Romano. *Lingual Orthodontics* B.C. Decker, London, 1998.
10. Kalang JT, Thomas RG. Thomas Indirect Bonding: A Comprehensive Review of the Literature. *Semin Orthod* 2007; 13: 3-10.
11. Echarri P, Kim TW. Double transfer trays for indirect bonding. *J Clin Orthod* 2004; 38: 8-13.
12. Millett DT, McCabe JF. Orthodontic bonding with glass ionomer cement – A review. *Eur J Orthod* 1996; 18: 385-99.
13. Kyung HM. The Use of Microimplants in Lingual Orthodontic treatment. *Semin Orthod* 2006; 12: 186-90.
14. McLaughlin RP, Bennet JC. Anchorage control during leveling and aligning with a preadjusted appliance system. *J Clin Orthod* 1991; 25: 687–96.
15. Geron S, Vardimon A. Six Anchorage Keys Used in Lingual Orthodontic Sliding Mechanics. *World J Orthod* 2003; 4: 258–65.
16. Takemoto K, Scuzzo G. The straight-wire concept in lingual orthodontics, *J Clin Orthod* 2001; 35: 46-52.
17. Lombardo L, scuzzo G, Takemoto K, Takemoto Y, and Takemot A. A new lingual Straight-wire technique, *J Clin Orthod* 2010; 44: 114-23.
18. Fillion D. Lingual Straight wire Treatment with the Orapix System, *J Clin Orthod* 2011; 45: 488-98.
19. Paige SF. A lingual light - wire technique. *J Clin Orthod* 1982; 16:534 – 544.
20. McCrostie HS. Lingual Orthodontics: The Future. *Semin Orthod* 2006; 12: 211-14.
21. Prieto M, Melleiro G, Prieto L. Adult Class II Treatment Using a New Lingual Bracket and Skeletal Anchorage. *J Clin Orthod* 2012; 46: 176-81.
22. Magali M, Fauquet C, Galletti C, Palot C, and Wiechmann D, Mah J. Digital design and manufacturing of the Lingual care bracket system. *J Clin Orthod* 2005; 39: 375-82.
23. Niansong Ye, Kefu Zhang, Wenli Lai, Jingtao Li, Yimin Yang. Computer-Aided Design of a Lingual Orthodontic Appliance Using Cone-Beam Computed Tomography. *J Clin Orthod* 2011; 45: 553-60.
24. Gilbert A. An in-office wire-bending robot for lingual orthodontics. *J Clin Orthod* 2011; 45: 230-34.
25. Shpack N, Geron S, Floris I, Davidovitch M, Brosh T, Vardimon A. Bracket Placement in Lingual vs Labial Systems and Direct vs Indirect Bonding. *Angle Orthod* 2007; 77: 509-17.

**Corresponding Author**

**Dr. Praveen chirivella ..BDS ( MDS) ,**  
 Post Graduate,  
 Department of Orthodontics, Narayana  
 Dental College, Nellore,  
 Andhra Pradesh, India -524003.  
**Phone No:-** 91-8686385001  
**E-mail-** praveenchirivella@gmail.com