

HISTOLOGICAL AND HISTOMETRIC ANALYSIS OF SOLITARY AND  
NON-SYNDROME ASSOCIATED MULTIPLE ODONTOGENIC KERATOCYSTS.

<sup>1</sup> Paremala K	<sup>1</sup> Reader
<sup>2</sup> Radhika M B	<sup>2</sup> Professor and Head
<sup>3</sup> Lalita J Thambiah	<sup>3</sup> Professor
<sup>4</sup> Monica C. Solomon	<sup>4</sup> Professor
<sup>5</sup> Nirmala N Rao	<sup>5</sup> Professor
<sup>6</sup> Gurkiran Kaur	<sup>6</sup> Reader

<sup>1,2,3</sup> Department of Oral Pathology, Krishnadevaraya College of Dental Sciences, Bangalore. <sup>4,5</sup> Department of Oral Pathology and Microbiology, Manipal College of Dental Sciences, Manipal, <sup>6</sup> Department of Oral Pathology, Gian Sagar Dental College and Hospital, Patiala, Punjab

ABSTRACT:

**Objectives:** Odontogenic keratocysts are common, locally destructive lesions of the head and neck region. They can occur as solitary or multiple lesions, and if multiple, they are mostly associated with Gorlin-Goltz syndrome. This study aims to categorize the OKCs which behave more aggressively, using conventional histopathological techniques.

**Methodology:** The present study exploits conventional histopathological techniques to gain an insight into the behavior of the OKC (both solitary and non-syndrome associated multiple OKCs). The histological features (keratinization pattern, presence of satellite cysts / odontogenic islands, epithelial infoldings and corrugations) and histometric parameters (total number of nuclei, epithelial height, total nuclear density, number of basal nuclei, basement membrane length, basal nuclear density and mitotic index) were compared between the two groups of cysts.

**Result:** Multiple OKCs exhibited increase in number of infoldings, corrugations, mitotic index, reduced epithelial height, total number of nuclei, number of basal nuclei, and basal nuclear density. This information may be used to predict their biologic behavior and thus serve as a basis for diagnostic and therapeutic strategies.

**Conclusion:** Conventional histopathological techniques can provide valuable information which may be useful to categorize those OKCs that have more aggressive biological behavior and helps in deciding the treatment protocol.

**KEYWORDS:** Odontogenic keratocyst, biologic behavior, recurrence, histometric analysis, mitotic activity.

INTRODUCTION

Cysts of the jaws, in particular Odontogenic Keratocysts has evoked considerable interest among clinicians, pathologists and basic scientists. Odontogenic Keratocysts (OKCs) make up 11.2% of all the odontogenic cysts<sup>1</sup>. They can occur as solitary or multiple cysts, and if multiple they most likely are part of the Naevoid basal cell carcinoma syndrome (Gorlin- Goltz syndrome)<sup>2</sup>. This syndrome is a pleiotropic autosomal disorder encompassing a spectrum of developmental disorders. OKCs are unique odontogenic lesions that have potential to behave aggressively. These cysts can attain impressive dimensions and have a marked tendency to recur (6-60%)<sup>3,4</sup>. Over the past decade advances in immunohistochemistry have provided

opportunities for studies on the cyst linings in an attempt to clarify its pathogenesis and to understand the unique biology of OKC. However, the present study exploits conventional histopathological techniques to obtain valuable information about the behavior of this cyst. The present study attempts to assess the aggressive nature of OKCs by comparing the histological features and histometrical parameters of solitary and multiple non-syndrome associated OKCs.

Materials and methods:

The samples for the study were retrieved from the archives of the Department of Oral Pathology. In total, 30 diagnosed cases of OKCs were selected.

Of these, 20 were solitary presentations of OKCs and the remaining 10 were multiple OKCs. Fresh sections of 5µm thickness were obtained from formalin fixed paraffin embedded blocks were stained with Hematoxylin and Eosin (H & E).

#### Criteria for histological analysis

- The epithelial length of 3cms was selected and keratinization pattern was examined.
- The cystic fibrous capsule was examined for satellite cysts and / or odontogenic islands<sup>5</sup>.
- The epithelium was examined for presence of infoldings into the connective tissue capsule. These were graded based on the number of infoldings per low power field as **mild** (1-3 infoldings '+'), **moderate** (3-6 infoldings '++'), or **severe** (> 6 infoldings '+++').
- The epithelium was examined for corrugations in the parakeratin layer, and was graded as **mild** (+) when < 1/3 of the epithelium, **moderate** (++) when > 1/3 but <2/3 of the epithelium and **severe** (+++) if > 2/3 of the total epithelium exhibited corrugations.

#### Histometrical analysis<sup>5</sup>

Measurements were done using the **40X objective** and eyepiece graticule. Three separate 100µm fields of epithelium along the luminal surface were examined.

- Total Number of Nuclei (TNN)** contained in the total epithelium thickness was counted.
- Epithelial height of each field from the basement membrane to the cystic lumen was measured at 3 equidistant points at right angles to the surface and the **Average Epithelial Height (EH)** was calculated for each field.
- The relation between the TNN and the EH was found to obtain **Total Nuclear Density** using the formula,
  - TND = TNN / EH
- In the same field, the **Number of Basal Nuclei (NBN)** was counted.
- The **Basement Membrane Length (BL)** was measured by projecting the section onto a CCTV screen and a thread was used to take into account, the basal irregularities. By extending the thread on a metric rule (of the graticule), the

real length of the basement membrane of each field was obtained.

- Then the **Basal Nuclear Density (BND)** was calculated as

$$\text{BND} = \text{NBN} / \text{BL}$$

#### Mitotic Index (MI)<sup>6</sup>

- The number of epithelial cells in the cystic lining was counted in 3 High Power Fields (HPFs) and the average was obtained.
- Total number of epithelial cells in 10 HPFs = Avg. of 3 HPFs X 10
- The number of mitotic figures was counted at random in 10 HPFs which were either in metaphase, anaphase or telophase and they were added ( $N_1 + N_2 + N_3 + \dots + N_{10}$ ).

Then the Mitotic Index is calculated by:

(Number of mitotic figures / Total number of epithelial cells) x 1000

#### Exclusion criteria

The sections were selected based on the histological integrity of the epithelium to the underlying connective tissue wall. So the cysts with extensive separation of the epithelium from the underlying fibrous wall were excluded. Care was taken to include only those areas containing little or no inflammation.

For each case, the measurements for all the 3 fields were tabulated, and their mean value was obtained for each parameter. Mann - Whitney U test was applied and the average for each parameter was obtained. The data for each parameter between the 2 groups was analyzed.

#### Results

All the cases were observed for histological features – type of keratinization, presence or absence of satellite cysts and / or odontogenic islands, corrugations and the number of epithelial infoldings. The histometrical parameters considered for evaluation were: Total Number of Nuclei (TNN), Epithelial Height (EH), Total Nuclear Density (TND), Number of Basal Nuclei (NBN), Basement Membrane length (BL), Basal Nuclear Density (BND), and Mitotic Index (MI).

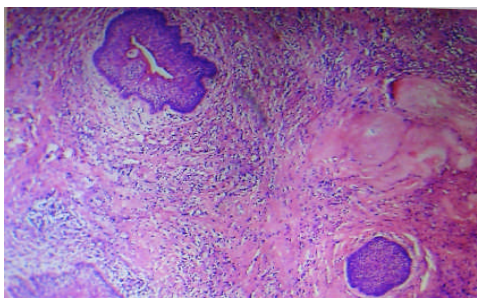


Fig.1: Photomicrograph showing odontogenic island and satellite cyst in the connective tissue wall of a solitary OKC. H& E stain (10 X).

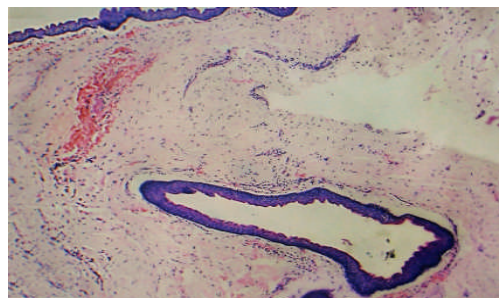


Fig. 2: Photomicrograph showing satellite cyst in the connective tissue wall of a multiple OKC. H& E stain (10 X).

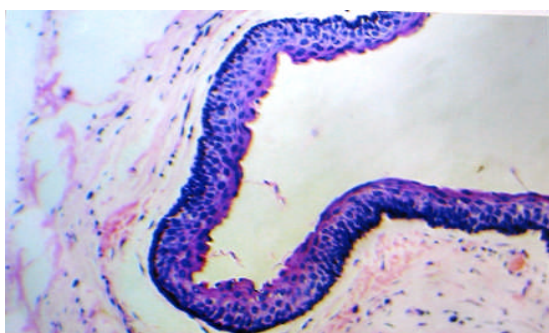


Fig. 3: Photomicrograph showing mild infoldings and corrugations of the epithelial lining of a solitary OKC. H & E stain (25 X)

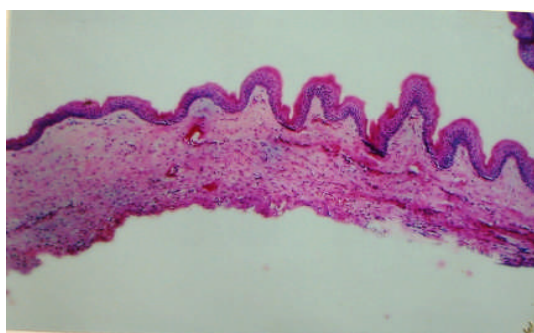


Fig.4: Photomicrograph showing numerous infoldings and corrugations of the epithelial lining of a multiple OKC. H& E stain (10 X).

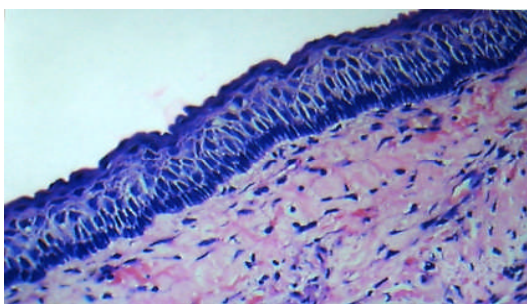


Fig. 5: Photomicrograph showing increased Epithelial Height, Basal Nuclear Density and Total Number of Nuclei in the epithelial lining of the solitary OKC. H& E stain (40X).

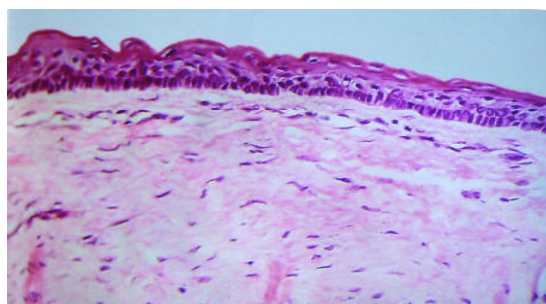


Fig.6: Photomicrograph showing reduced Epithelial Height, Basal Nuclear Density and Total Number of Nuclei in the epithelial lining of the multiple OKC. H& E stain (40 X)

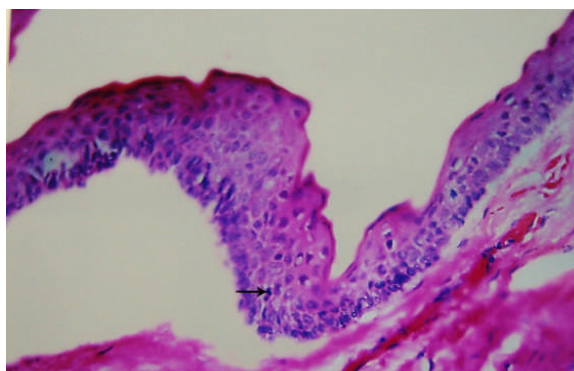


Fig. 7: Photomicrograph showing a mitotic figure in the suprabasal layers of a multiple OKC. H& E stain (40 X).

Table I: Comparison of histological features between the solitary and multiple OKCs

S.No	Parameter	Solitary OKCs (n=20)		Multiple OKCs (n=10)		P
		Number	%	Number	%	
1	Parakeratinization	19	95	10	100	1 (NS)
2	Satellite cysts / Odontogenic islands	14	70	8	80	0.518 (NS)
3	Infoldings					0.005 (HS)
	Mild	11	55	-	-	
	Moderate	6	30	2	20	
	Severe	3	15	8	80	
4	Corrugations					0.048 (S)
	Mild	10	50	-	-	
	Moderate	7	35	7	70	
	Severe	1	5	3	30	

NS: Non-significant    S: Significant    HS: Highly significant

The measurements were done by two observers to prevent any personal bias and were subjected to Mann-Whitney U test. This was found to be statistically non-significant. In the present study for parakeratinization pattern using Fischer's exact test, it was found to be non-significant between the two variants (**Table.1**). All the cases of OKCs were observed for satellite cysts and / or odontogenic islands (**Fig.1** and **Fig. 2**). When subjected to statistical analysis using the Chi-square test, the p-value obtained was non-significant (**Table.1**). The number of infoldings per low power field was evaluated in all the OKC lesions (**Fig.3** and **Fig. 4**). Multiple OKCs exhibited more of moderate and severe infoldings (**Table.1**).

Solitary cases exhibited mild corrugations (Figure 3), whereas the multiple OKCs exhibited moderate and severe corrugations (Figure 4). This feature when subjected to Chi-square test, showed a significant p-value. (**Table.1**).

In the present study, the mean TNN, mean EH, mean NBN and mean BND (**Fig.5**) obtained for the solitary cases were more than the same for the multiple cases (**Fig.6**). On subjecting the above parameters to Mann-Whitney U test, the p-value was highly significant. The mean TND was more for multiple cases than for the solitary OKCs. This parameter was subjected to statistical analysis using Mann-Whitney U test and the p-value obtained was

non- significant. Further, the mean value of BL was evaluated. It was higher in solitary OKCs than in multiple cases. This when subjected to Mann-Whitney U test, the p-value obtained was non-significant. In addition, the mean MI was less for the solitary cases than for the multiple variants of OKCs (**Fig.7**). By subjecting to Mann-Whitney U test the p-value of was highly significant.

On comparing the solitary and multiple cases of OKCs, the histological features that were found to be significant using Chi-Square test were the number of infoldings, and extent of corrugations. In addition, the histometrical parameters that were found to be significant using Mann-Whitney U test were: Total Number of Nuclei (TNN), Epithelial Height (EH), Number of Basal Nuclei (NBN), Basal Nuclear Density (BND) and Mitotic Index (MI).

Discussion

OKC is a distinct odontogenic cyst because of its unique clinical presentations, histological features, and aggressive biological behavior with a greater tendency for recurrence. Several investigators have highlighted the intrinsic growth potential of the epithelial lining. They can occasionally occur as a component of the Basal cell naeviod syndrome in which there is some inherent, presumably genetic potential for proliferation of odontogenic epithelium which is reflected in the multiplicity of the cysts at

different sites. Multiple keratocysts may also occur in many patients without any overt features of the syndrome due to a genetic predisposition.

OKCs are characterized by distinct histopathological features of a thin and uniform epithelium of 6-10 layers thickness with palisaded and polarized arrangement of basal cell nuclei and has thin underlying connective tissue capsule. In the present study 95% of solitary and 100% of multiple keratocysts exhibited parakeratinization. This finding is in accordance with the previous studies done by Brannon RB<sup>7</sup>, Browne R J<sup>8</sup>, Wright JM<sup>9</sup> who have stated that cysts with parakeratinized epithelium are more aggressive than the orthokeratinized variants. The observation of this feature in the present study suggests that multiple OKCs do not differ significantly from their solitary variants in the keratinization pattern. In the present study satellite cysts and / or odontogenic islands were observed in 70% of solitary cases and 80% of multiple OKCs (Table I). Brannon RB<sup>7</sup> and Ahlfors E et al<sup>2</sup> and Woolgar JA et al<sup>10</sup> also observed greater frequency of satellite cysts in the connective tissue wall of the multiple and syndrome associated OKCs when compared to solitary variants. This suggests a greater proliferative potential of the multiple OKCs. In the present study severe infoldings were observed in 15% of the solitary OKCs in contrast to 80% in multiple variants (Table I). This is in accordance with the study of Ahlfors E et al<sup>2</sup> who proposed that infoldings are the result of the cystic epithelium being pushed into the capsule by active proliferation and eventually leading to the enlargement of the cysts by the resorption of the adjacent alveolar bone wall, thus indicating the aggressive nature of the multiple keratocysts.

Further, we observed that 5% of the solitary and 30% of the multiple OKCs exhibited severe amount of corrugations. According to Wysocki GP and Sapp JP<sup>11</sup> this characteristic feature of the cyst may be related to the increased cellularity and cellular crowding which occurs at their epithelial surface. This is suggestive of a highly active epithelium of multiple OKCs and correlates with its increased mitotic activity as demonstrated by Browne<sup>8</sup>. Similarly, in the present study, the multiple OKCs with severe corrugations showed a greater Mitotic Index than the solitary variants with severe corrugations. In the present study the mean TNN and EH was found to be significantly higher in

solitary OKCs compared to the multiple variants. This suggests that there is a gradual and slow migration and maturation of the cells through the epithelial cell layers, thereby retaining more number of cells within the epithelium in solitary variants. This is in contrast to the multiple variants which exhibit rapid migration and maturation of epithelial cells and an increased turnover rate of the epithelium. These findings are in accordance with the results obtained by Dominguez FV and Keszler A<sup>5</sup>. However, the TND was found to be more in the multiple OKCs when compared to their solitary variants. It reflects that the epithelial cells of the multiple OKCs are more active than the epithelial cells of the solitary variants. In addition, in the present study the higher NBN and BND in the solitary OKCs may be due to slower cell migration and maturation through the epithelial cell layers, and thus the basal cells may be retained in the proliferation compartment. It can also be due to a non-invasive localized growth of the germinative layer. Whereas in the multiple variants, reduced NBN and BND suggests that due to the rapid turnover rate, the basal cells do not remain in the proliferation compartment and it can also be due to greater lateral expansion of the cystic epithelium. This is in accordance with the views put forward by Dominguez FV and Keszler A<sup>5</sup> who stated that BND was an adequate parameter for the evaluation of growth potential or chances of recurrence.

Mitotic Index (MI) is recognised as a reliable criterion to define the growth potential of a lesion. In the present study MI was more in multiple OKCs than in the solitary variants which suggests a higher activity of the epithelial lining in them. This increased MI may be responsible for its extensive growth reflecting its aggressive behavior when compared to its solitary variants. Toller PA<sup>12</sup> showed autoradiographically that mitotic activity is consistent with its rapid turnover rate. It appears that the superficial cells are readily dislodged and rapidly replaced by succeeding generation of cells due to apparent lack of adhesion between the epithelial cells. Main DMB<sup>13</sup> has found that the proliferative rate of OKCs were comparable to that of ameloblastomas. Shear M<sup>14</sup> has also shown that OKCs have an increased growth potential, expressed by a higher mitotic and proliferative indices than that in other odontogenic cysts, and stated that the activity in the epithelial lining was the causes for the aggressive behavior of the cyst. Thus the present study demonstrates that the OKCs that

exhibit severe infoldings and corrugations, reduced Total Number of Nuclei, Epithelial Height, Basal Nuclear Density, Number of Basal Nuclei, and increased Mitotic Index are more aggressive in nature.

### SUMMARY AND CONCLUSION

In the present study histological and histometrical differences were noted between the two variants of OKCs, wherein the multiple variants exhibited increased number of infoldings, corrugations, reduced epithelial height, total number of nuclei, number of basal nuclei and basal nuclear density and an increase in the mitotic index when compared to the solitary variants. Thus we can conclude that conventional histopathological techniques can provide valuable information which may be useful to categorize those OKCs that have more aggressive biological behavior and helps to decide the treatment protocol. Therefore these patients may be kept under regular follow up and also should be evaluated for any other possible features of Nevoid basal cell carcinoma syndrome.

### References:

1. Shear M: Cysts of the oral regions. 3rd edi. Oxford, UK, Batterworth- Heinemann Ltd, 1992,6.
2. Ahlfors E, Larsson A, Sjogren S: The Odontogenic Keratocyst: A Benign cystic tumor? J Oral Maxillofac Surg 1984; 42: 10-19. doi:10.1016/0278-2391(84)90390-2
3. Vedtofte P, Pretorius F: Recurrence of the Odontogenic keratocyst in relation to clinical and histological features. A 20 year follow up study of 72 patients. Int J Oral Surg 1979; 8: 412-420. doi:10.1016/S0300-9785(79)80079-4
4. Magnusson BC: Odontogenic Keratocysts: A clinical and histological study with special reference to enzyme histochemistry. J Oral Pathol 1978; 7: 8-18. doi:10.1111/j.1600-0714.1978.tb01880.x
5. Dominguez FV and Keszler A: Comparative study of keratocysts, associated and non-associated with nevoid basal cell carcinoma syndrome. J Oral Pathol 1988; 17: 39-42. doi:10.1111/j.1600-0714.1988.tb01503.x
6. Leary TJ and Steffes MW: Can you count on the mitotic index. Human Pathol 1996; 28: 328-333.
7. Brannon RB: The Odontogenic keratocyst. A clinicopathological study of 312 cases. Part II. Histological features. Oral Surg Oral Med Oral Pathol 1977; 43: 233-255. doi:10.1016/0030-4220(77)90161-X
8. Browne RM: The Odontogenic keratocyst Histological features and their correlation with the clinical behavior. Br Dent J 1971; 131:249-259. PMID:5286040 doi:10.1038/sj.bdj.4802732
9. Wright JM: The Odontogenic Keratocyst. Orthokeratinized variety. Oral Surg Oral Med Oral Pathol 1981; 51: 609-618. doi:10.1016/S0030-4220(81)80011-4
10. Woolgar JA, Rippin JW and Browne RM: A comparative histological study of odontogenic keratocysts in basal cell nevus syndrome and control patients J Oral Pathol 1987; 16:75-80. doi:10.1111/j.1600-0714.1987.tb00691.x
11. Wysocki GP and Sapp JP: Scanning and Transmission electron microscopy of odontogenic keratocysts. Oral Surg Oral Med Oral Pathol 1975; 40: 494-501. doi:10.1016/0030-4220(75)90247-9
12. Toller PA: Autoradiography of explants from odontogenic cysts. Br Dent J 1971; 131: 57-61. PMID:5283539 doi:10.1038/sj.bdj.4802700
13. Main DMG: Epithelial jaw cysts. A clinicopathological reappraisal. Br J Oral Surg 1970;8:114-125. doi:10.1016/S0007-117X(70)80002-6
14. Shear M: The aggressive nature of the odontogenic keratocyst – Is it a benign cystic neoplasm 2. Proliferation and genetic studies. Oral Oncol 2002; 38: 323-331. doi:10.1016/S1368-8375(01)00066-5

### Corresponding Author

**Dr.Paremala.K**

Reader

Department of Oral Pathology,  
Krishnadevaraya College of Dental Sciences,  
Bangalore.

Mobile:+919844244822

Email:paremala@gmail.com