

GEMINATION IN PRIMARY TEETH – A Report of Two Clinical Cases

* Tarasingh. P , ** Balaji. K

*Asst. Professor.

** Associate Professor

Department of Pedodontics and Preventive Dentistry, SVS Institute of Dental Sciences, Mahabubnagar, Andhra Pradesh.

ABSTRACT

Geminated teeth are the consequences of developmental anomalies leading to the eruption of joined elements. According to the current definitions, gemination occurs when one tooth bud tries to divide, while fusion occurs if two tooth buds unite. This article presents two unique cases of gemination of right primary maxillary central incisors. Authors conclude that geminated teeth in primary dentition have to be carefully analyzed as they may be associated with anomalies in the permanent dentition. Correct diagnosis of the condition implicates in a better prognosis for the patient.

KEYWORDS: Gemination, Fusion, Primary teeth

INTRODUCTION

Developmental dental disorders may be due to abnormalities in the differentiation of the dental lamina and the tooth germs (anomalies in number, size and shape) or to abnormalities in the formation of the dental hard tissues (anomalies in structure). In some, both stages of differentiation are abnormal. Developmental dental disorders are not only congenital but they may also be inherited, acquired or idiopathic. The terms “double tooth”, “double formations”, joined teeth”, or “fused teeth” are often used to describe gemination and fusion, both of which are primary developmental abnormalities of the teeth.¹⁻⁷

In 1963, Tannenbaum and Alling,⁸ defined gemination as the formation of the equivalent of two teeth from the same follicle, with evidence of an attempt for teeth to be completely separate, this indicated clinically by a groove or depression which could delineate two teeth. Radiographically, there appears to be only one pulp chamber. They stated that in germination, if the bifid tooth is counted as one entity, the total number of teeth in the dental arch is otherwise normal.

Gemination of primary teeth is more frequent than among permanent teeth. Data available for the primary dentition combined the prevalence of fused and geminated teeth, the conditions being relatively frequent, ranging from 0.5 percent to 2.5 percent according to the population surveyed.⁹⁻¹¹

The etiology is unknown, but trauma has been suggested as a possible cause, though a familial tendency has been suggested.¹² Gemination is observed in the deciduous as well as in the permanent dentition.^{3,4,7}

In the anterior region, this anomaly can cause unpleasant esthetic appearance due to irregular morphology. If a deep groove is present, these teeth may be susceptible to caries and periodontal disease and may require endodontic intervention in some cases which may be complicated.^{1,2}

This article reports on two cases of gemination of right primary maxillary central incisors with a discussion of clinical implications and treatment methods with respect to the different types and morphological variations of geminated teeth.

Fig. 1

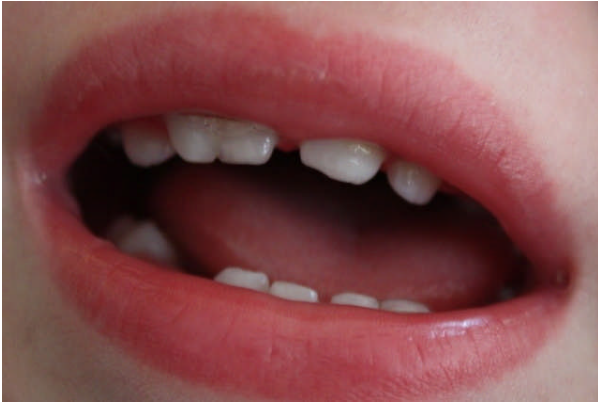

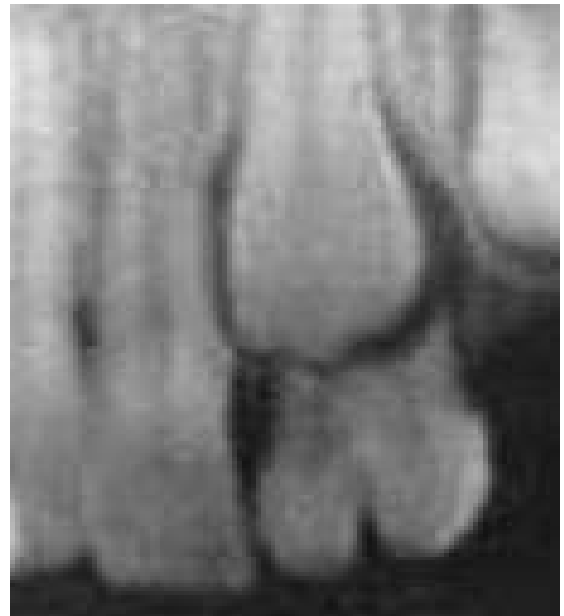
Fig. 3

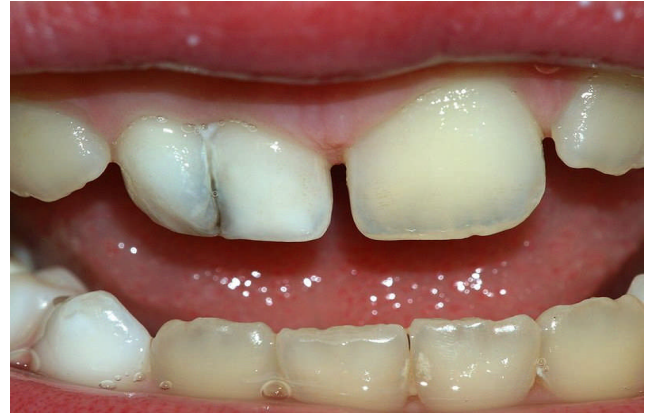

Fig. 2

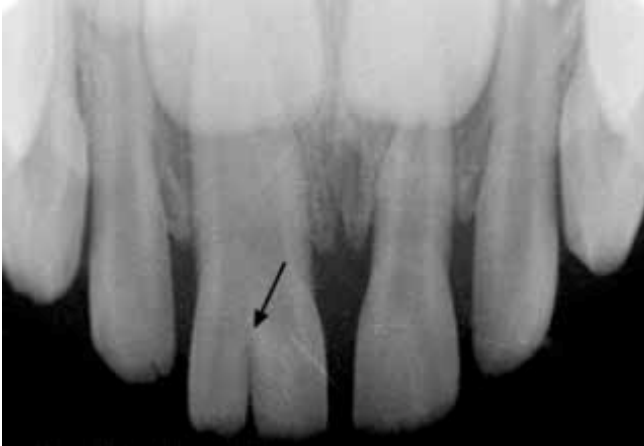

Fig. 4



CASE REPORTS

Case Report 1:-

A 2 year old boy was brought to the Department of Pedodontics and Preventive Dentistry, SVS Institute of Dental Sciences, Mahabubnagar with a chief complaint of large front teeth. The Clinical extraoral examination did not show any different alteration. The clinical intraoral examination revealed the presence of geminated 51 (Fig 1). The patient has 16 teeth and oral structures showing normal pattern. No other anomalies were found. Radiographic Examination revealed the presence of single pulp chamber and root canal (Fig 2), which is one of the distinguishing features of geminated teeth from fusion.

Case Report 2:-

An 8 year old male patient reported to the Department of Pedodontics and Preventive Dentistry, SVS Institute of Dental Sciences, Mahabubnagar with a complaint of large, unsightly appearance of front teeth. No other member of the family was affected with similar dental anomalies. Clinical examination revealed the presence of an irregular morphology of right Primary maxillary central incisor. The maxillary dental arch presented one large Primary central incisor that was abnormally wide and had bifid crown (Fig 3). The incisor showed a buccal and palatal groove from the incisal edge to the cervical portion of the tooth. The initial caries lesion was noted on the labial groove of the primary central incisor. The Periapical radiography showed the incisor had a single root & root canal (Fig 4).

Discussion

The terminology dental fusion and gemination are used to define two different morphological dental anomalies, characterized by the formation of a clinically wide tooth. Despite the considerable number of cases reported in the literature, the differential diagnosis between these abnormalities is difficult. Case history and clinical and radiographic examinations can provide the information required for the diagnosis of such abnormalities.^{1,3-6,16} After a judicious evaluation of all information we can report that these cases represents gemination of primary maxillary central incisors.

The use of 'Levitas' classification to distinguish between cases of fusion and gemination is very practical.¹³ The differential diagnosis between fusion and gemination, based on the number of teeth present on the dental arch, is not, however, always possible.⁵ This is because nothing impairs the fusion between a "normal" and a supernumerary element while the contiguous "normal" tooth is congenitally absent, resembling clinical cases of gemination.^{5,6}

The phenomenon of gemination arises when two teeth develop from one tooth bud and, as a result, the patient has a larger tooth but a normal number, in contrast to fusion where the patient would appear to be missing one tooth.^{3,4,6,7} Fused teeth arise through union of two normally separated tooth germs, and depending upon the stage development of the teeth at the time union, it may be either complete or incomplete. On some occasions, two independent pulp chambers and root canals can be seen. However, fusion can also be the union of a normal tooth bud to a supernumerary tooth germ. In these cases, the number of teeth is also normal and differentiation from gemination may be very difficult, if not impossible. In geminated teeth, division is usually incomplete and results in a large tooth crown that has a single root and a single canal.^{1,3,5} This anatomic irregularity occurs more often in the deciduous than in the permanent dentition. Only a few cases of fusion involving molar and premolar teeth have been reported whereas, in both dentitions, the prevalence is higher in the anterior region.^{3,4,6,12,13}

The anomaly can cause unpleasant esthetic appearance due to irregular morphology. When deep grooves are present, these teeth may be susceptible to caries and periodontal disease and may require endodontic intervention in some cases which may be complicated.^{3,4,16,17}

The main periodontal complication in gemination cases occurs due to the presence of fissures or grooves in the union between the teeth involved. If these defects are very deep and extend subgingivally, the possibility of bacterial plaque accumulation in this area is quite high. Strict oral hygiene is imperative to maintain periodontal health. Furthermore, gemination may have an adverse effect on occlusion, causing deviation and, sometimes, delaying the eruption of other teeth with

aesthetic problems resulting from tooth.² In these cases, despite of buccal grooves in the primary maxillary centrals no serious periodontal disease was evident except delaying the eruption of successor in case report 2.

Difficult cases include a wide spectrum of problems.^{13,16} The best way to manage these difficult cases depends on a number of factors including the knowledge and technical skills of the practitioner.^{1,13-17}

CONCLUSION

Gemination of primary teeth presents several problems to the clinician. Since exfoliation times are usually different for each tooth involved in the gemination, consideration should be given to the variations in root resorption. In present cases, in case report 2, the geminated primary incisors lead to delayed eruption of its successor. Geminated teeth may also contribute to esthetic concerns, space problems & occlusal disturbances. Hence, careful monitoring of the condition is recommended.

REFERENCES

1. Aguilo L, Gandia JL, Cibrian R, Catala M. Primary double teeth. A retrospective clinical study of their morphological characteristics and associated anomalies. *Int J Paediatr Dent* 1999;9:175-183.
2. Blank BS, Ogg RR, Levy AR. A fused central incisor. Periodontal considerations in comprehensive treatment. *J Periodontol* 1985;56:21-24.
3. Carroll MK. Fusion and gemination in alternate dentitions. *Oral Surg* 1990;69: 655.
4. Maibaum WW. Fusion of confusion? *Oral Surg Oral Med Oral Pathol* 1990;69: 656-657.
5. Reilly PMR. Structural and radiographic evaluation of four cases of tooth fusion. *Aust Dent J* 1990;35:226-229.
6. Terezhalmay GT, Riley CK. Gemination/fusion. *Quintessence Int* 1999;30:437.
7. Duccan WK, Helpin ML. Bilateral fusion and gemination: a literature analysis and case report. *Oral Surg Oral Med Oral Pathol* 1987;64:82-87.
8. Tannenbaum KA and Alling EE. Anomalous tooth development: case reports of germination and twinning. *Oral Med and Oral Path* 1963;16:883-887.
9. Grahn H and Granath L. Numerical variations in primary dentition and their correlation with the permanent dentition. *Odont Rev* 1961;12:248-257.
10. Clayton JM. Congenital dental anomalies occurring in 3, 557 children. *J Dent Child* 1956;23:206-208.
11. Niswander JD and Surijaker C. Congenital anomalies of teeth in Japanese children. *Amer Phys Anthrop* 1963;21:569-574.
12. Jarvinen S, Lehtinen L, Milen A. Epidemiologic study of joined primary teeth in Finnish children. *Community Dent Oral Epidemiol* 1980;8:201-202.
13. Neves AA, Neves MLA, Farinhas JA. Bilateral connotation of permanent mandibular incisors: a case report. *Int J Paediatr Dent* 2002;12:61-65.
14. Nunes E, De Moraes IG, De Novaes PMO, De Sousa SMG. Bilateral fusion of mandibular second molars with supernumerary teeth: Case Report. *Braz Dent J* 2002;13:137-141.
15. Velasco LF, De Araujo FB, Ferreira ES, Velasco LE. Esthetic and functional treatment of a fused permanent tooth: a case report. *Quintessence Int* 1997;13: 677-680.
16. Milano M, Seybold SV, McCandless G, Cammarata R. Bilateral fusion of the mandibular primary incisors: report of case. *ASDC J Dent Child* 1999;66:280-282.
17. Peretz B, Brezniak N. Fusion of Primary mandibular teeth. Report of Case. *ASDC J Dent Child* 1992;59:366-368.

Corresponding Author :

P. Tarasingh MDS

Asst. Professor

Dept of Pedodontics and Preventive Dentistry,
SVS Institute of Dental Sciences,
Mahabubnagar, Andhra Pradesh.

Ph: 91-995-174-9730

Email:dr_tara_singh@yahoo.com