

EXTRAVASATED MUCOCELE ON LOWER LIP - A CASE REPORT

<sup>1</sup> Priya Singhal  
<sup>2</sup> Maitrey Bhalodia  
<sup>3</sup> Manoj Vengal

<sup>1</sup> Post graduate student  
<sup>2</sup> Post graduate student  
<sup>3</sup> Professor and Head

<sup>1-3</sup> Department of Oral Medicine and Radiology, Vyas Dental College and Hospital, Jodhpur(RAJASTHAN) ,INDIA

**ABSTRACT:** Mucocoeles can appear as Extravasation or Retention type. Lower lip is the most common site for Extravasation type. Mucocoeles are usually painless but sometimes they may cause difficulty in speaking and chewing. Their sudden appearance often makes the patients anxious. Simple surgical excision when done with care is the best treatment alternative that can relieve the patients fear and anxiety. Here we present a case report of 19-year-old boy with mucocoele of extravasation type on lower lip treated with surgical excision.

**KEYWORDS:** Mucocoele ,Traumatic lesion,Extravasation cyst

INTRODUCTION

“Mucocoele” is a clinical term that describes swelling caused by the accumulation of saliva at the site of a traumatized or obstructed minor salivary gland duct<sup>1</sup>. It can also be described as a cystic space filled with mucinous material<sup>2</sup>. Mucocoeles are the most common minor salivary gland disorder, and represent the second most frequent benign soft tissue tumors of the oral cavity. Their incidence is 2.5 lesions per 1000 patients<sup>3</sup>. Clinically they appear as dome-shaped, translucent whitish-blue cystic lesions, papules or nodules that can range from a few millimeters to a few centimeters in diameter. On palpation they are non tender, smooth surfaced, fluctuant swellings. The lower lip is the most frequent site for a mucocoele as it is the most probable place for a trauma, and it is rarely seen on the upper lip, retromolar pad or palate.<sup>4</sup>

Case Report

A 19 year-old male patient reported to the dental clinic with the complaint of swelling on left side of lower lip. History of presenting illness revealed that it had started as a small sized swelling 10 months back which used to regress and reappear with occasional watery discharge from it. The swelling gradually increased in size and became constant since last 6 months. Patient gave history of habit of occasional lip sucking. No history of fever, malaise was present. On clinical examination it was noted that a dome shaped translucent nodular swelling with slightly bluish hue was present on the left side of lower lip measuring roughly 2x3 cm (**Fig-1a,b**). On palpation it was smooth surfaced, fluctuant and non tender. No bleeding was present on palpation. Differential Diagnosis included angiomatous lesions, Traumatic Fibroma, Lipoma and Salivary gland tumor. Investigations included Aspiration of the fluid from the swelling and Diascopy test. Aspirated

fluid was watery and transparent (**Fig-2**) and no blanching was seen on Diascopy. So final diagnosis was given on the basis of history and clinical features such as site, fluctuation, variation in size and its sudden appearance. Treatment planning consisted of surgical excision. Mucocoele was excised after doing required hematological investigations and sent for histopathological examination (**Fig.3 and Fig. 4**) which further confirmed the diagnosis. Regular recall and checkup for the reoccurrence of the lesion was done. In subsequent visits healing was good and no sign of recurrence was seen.

Discussion

The term Mucocoele is derived from Latin terms mucus, or mucus, and coele, or cavity<sup>5</sup>. Mucocoeles normally appear in the glands that secrete predominantly mucous saliva therefore they are more frequently found in the minor salivary glands. They can also be found with less frequency in the major salivary glands. Mucocoele located in the floor of the mouth is called as Ranula where sublingual glands are affected. Mucocoele can be superficial or deep. Superficial lesions frequently have a characteristic blue hue while deeper lesions can be covered by normal-appearing mucosa without the distinctive blue color and are more diffuse. Mucocoele may occur at any age, but is seen most frequently in the second and a third decade of life. It is seen more frequently in children, adolescents and young adults with no sex predilection<sup>5</sup>. Mucocoeles are either Extravasation or Retention type. There is no clinical difference between extravasation and retention mucocoeles but their etiology is different and they are different histopathologically. Mucocoeles most frequently occur on the lower lip, where trauma is common. The buccal mucosa, tongue, floor of

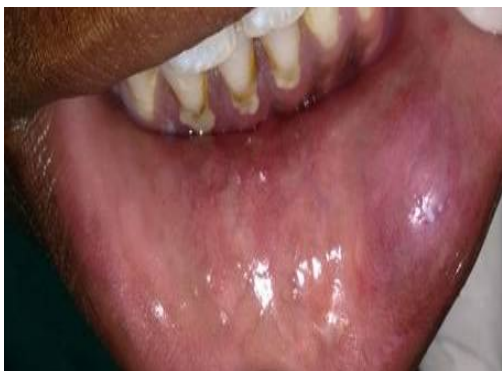
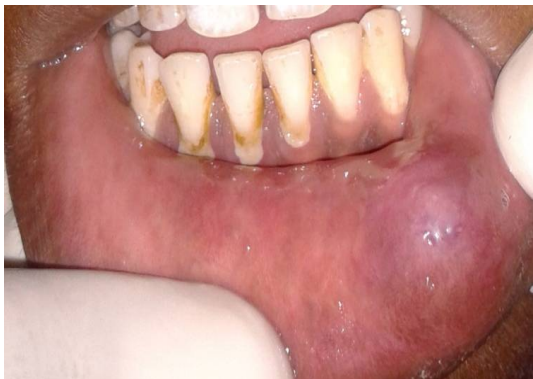
Fig 1a,b-Dome shaped translucent swelling with slight bluish hue on left side of Lower lip



Fig 2-Clear,transparent watery fluid after aspiration

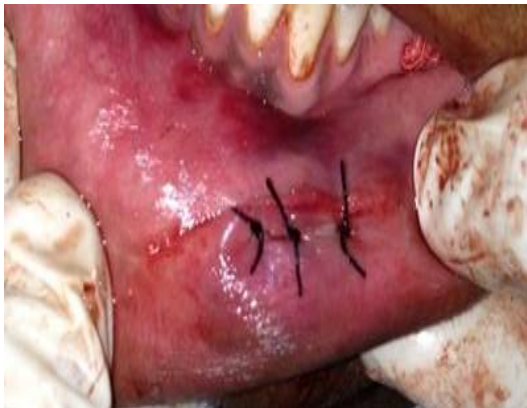
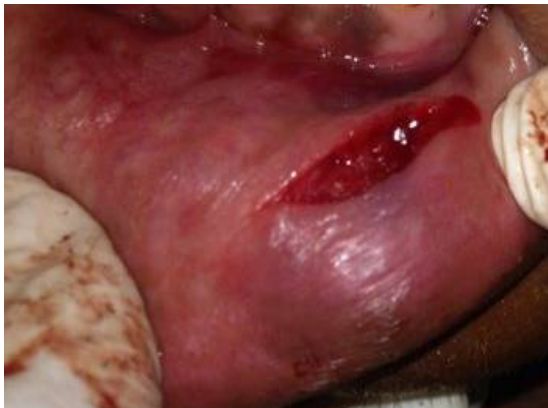
Fig3-Excision of Mucocyst followed by suture placement

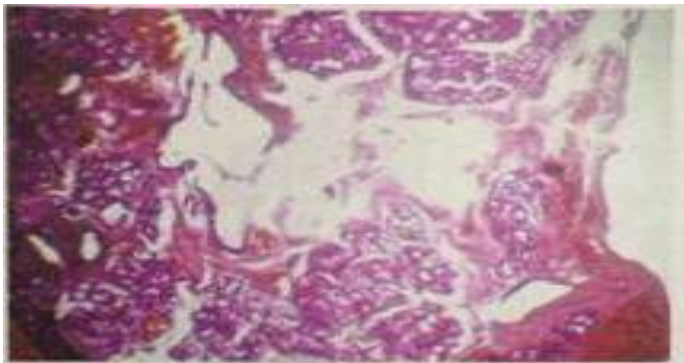


Fig. 4.Histopathological picture showing connective tissue stroma in which salivary acini are seen separated by connective tissue septa. Inflammation is seen with areas of mucilage spillage.

the mouth, and retromolar region are other commonly traumatized areas the mouth, and retromolar region are other commonly traumatized areas where mucous extravasation may be found. Mucous retention cysts are more commonly located on the palate or the floor of the mouth. Extravasated mucocoeles occur as a result of **trauma** to the minor salivary gland duct. Laceration results in the pooling of saliva in the adjacent submucosal tissue and consequent swelling. They do not have an epithelial cyst wall. Retention cysts are caused by **obstruction** of a minor salivary gland duct by calculus or possibly by the contraction of scar tissue around an injured duct. Blockage of salivary flow results in accumulation of saliva and dilation of the duct. Eventually, an aneurysm –like lesion forms, which can be lined by epithelium of the dilated duct<sup>6</sup>.

Histopathologically Extravasation mucocoeles are pseudocysts without defined walls. The extravasated mucous is surrounded by a layer of inflammatory cells and then by a reactive granulation tissue made up of fibroblasts caused by an immune reaction. Even though there is no epithelial covering around the mucosa, this is well encapsulated by the granulation tissue. In the case of retention mucocoeles a cyst cavity can be found, this is generally well defined with an epithelial wall covered with a row of cuboidal or flat cells produced from the excretory duct of the salivary glands. Compared to extravasation mucocoeles, retention mucocoeles show no inflammatory reaction and are true cysts with an epithelial covering<sup>7,8</sup>. Surgical excision is the most common treatment for mucocoele. For the surgical removal of the mucocoele, an elliptical incision is the most popular one. This helps to decrease the extent of mucosal tissue loss, decreases the incidence of formation of large fibrous scars and helps to prevent spilling of the cystic content, which could be responsible for its recurrence<sup>9</sup>. In the case of retention type it is important to surgically resect the lesion with its epithelial wall to ensure complete removal & reduce chances of recurrence. Large lesions may be marsupialized to prevent significant loss of tissue or to decrease the risk for significantly traumatizing the labial branch of the mental nerve<sup>10</sup>. Cryosurgery, intralesional corticosteroid injection, micro marsupialization, marsupialization of the mucocoele, laser ablation are the other treatment modalities for the mucocoeles<sup>11</sup>.

## CONCLUSION

Mucocoeles are the most common soft tissue growths of the oral cavity with trauma being a leading cause. Though asymptomatic may sometimes pose difficulties in speaking and chewing. Sudden and tumor like appearance of mucocoeles often develop fear in the patients. Proper diagnosis chiefly based on history and clinical features

and institution of appropriate treatment may relieve the patients from fear.

## References

1. Greenberg, Glick, Ship. Burket's Oral Medicine. 11ed. Ontario BC Decker. 2008, pg. 202.
2. Gupta Bhavna, Anegundi R, Sudha P, Gupta Mohit. Mucocoele: Two case reports J Oral Health Comm Dent 2007; 1(3): 56-58.
3. Jose Yague-García, Antonio-Jesus Espana-Tost, Leonardo Berini-Aytes, Cosme Gay-Escoda. Treatment of oral mucocoele-scalpel versus CO2 laser. Med Oral Patol Oral Cir Bucal 2009; 14(9): 469-74.
4. Nitin Singh, Pratik Chandra, Sugandha Agarwal. Oral Mucocoele: A Case Report. Journal of dentofacial sciences 2014; 3(1): 47-50.
5. Baumash HD. Mucocoeles and ranulas. J Oral Maxillofac Surg 2003; 61: 369-78.  
<http://dx.doi.org/10.1053/joms.2003.50074>
6. JAta-Ali et al. Oral mucocoele: review of the literature. J Clin Exp Dent 2010; 2(1): 18-21.  
<http://dx.doi.org/10.4317/jced.2.e18>
7. Wen-Chen Wang et al. Concurrent Extravasation Mucocoele and Epidermoid Cyst of the lower Lip: A Case Report. Kaohsiung J Med Sci 2005; 21: 475-9.  
[http://dx.doi.org/10.1016/S1607-551X\(09\)70154-8](http://dx.doi.org/10.1016/S1607-551X(09)70154-8)
8. A.K. Rashid, N. Anwar, A.M. Azizah, K.A. Narayan. Cases of mucocoele treated in the Dental Department of Penang Hospital. Archives of Orofacial Sciences 2008; 3(1): 7-10.
9. Nidhi Madan, Arun Rathnam. Excision of Mucocoele: A Surgical Case Report. Biological and Biomedical Reports 2012; 2(2): 115-118.
10. Pawan Raj, Rishab Malhotra, Prashant Babaji, Shamsheer Singh. Mucocoele-A Case Report. Dental Impact 2014; 6: 42-45.
11. Sukhtankar LV, Mahajan B, Agarwal P. Treatment of Lower lip Mucocoele with Diode Laser –A Novel Approach. Annals of Dental Research 2013; 2 (1): 102-108

## Corresponding Author

**Dr. Priya Singhal**

Department of Oral Medicine Diagnosis  
and Radiology

Vyas Dental College and Hospital  
Jodhpur (RAJASTHAN) -- 342001, INDIA  
Email. Id : prsinghal95@gmail.com