

---

**ENDODONTIC MANAGEMENT OF RADIX ENTOMOLARIS - TWO CASE REPORTS**

\*Rambabu. T

*\* Professor, Department of Conservative Dentistry & Endodontics, Vishu Dental College, Bhimavaram, Andhra Pradesh, India.*

---

**ABSTRACT.**

A mandibular first molar with two distal roots is an interesting example of anatomic variation. This paper describes 2 case reports of mandibular first molar with three roots (one mesial and two distal) and four canals (two in mesial and one in each distobuccal and distolingual root). The canals were shaped with protaper rotary files and irrigated with 2.5% sodium hypochlorite and 0.2 %w/v of chlorhexidine gluconate and normal saline as the final irrigant. The prevalence, the external morphological variations and internal anatomy of the radix entomolaris and paramolaris are described.

**KEY WORDS :** *Endodontic treatment, mandibular molar, radix entomolaris, radix paramolaris.*

---

**INTRODUCTION**

Treatment of mandibular molars have always kept the endodontist at risk and alert as it is one of the teeth that show variations in its external and internal morphology to the extreme. A major anatomical variant of the two-rooted mandibular first molar is a tooth with an additional distolingual and third root: the Radix Entomolaris. This reaches its epitome in the presence of an additional root located lingually (the radix entomolaris) or buccally (the radix paramolaris). When present an awareness and understanding of this unusual root and its root canal morphology contributes to the successful outcome of root canal treatment as unfilled canals remain a nidus for infection and can compromise treatment outcome.

**Review of literature**

The mandibular first molar can display several anatomical variations. The common morphology that first molars exhibit is two-rooted with two mesial and one distal canal<sup>1,2</sup>. Commonly the mesial root has two root canals, ending in two distinct apical foramina. Sometimes these merge together at the root tip to end in one foramen. The distal root typically has one kidney-shaped root canal, although if the orifice is particularly narrow and round, a second distal canal may be present<sup>3</sup>. The number of roots may also vary<sup>4</sup>. An additional third root, first mentioned in the literature by

Carabelli<sup>5</sup>, is called the radix entomolaris (RE). This supernumerary root is located distolingually in mandibular molars. RE was found on the first, second and third mandibular molars, occurring least frequently on the second molar. Some studies reported a bilateral occurrence of the RE from 50% to 67%. Similarly additional root in the mesiobuccal side is called the radix paramolaris (RP). The identification and external morphology of these root complexes, containing a lingual or buccal supernumerary root, are described by Carlsen and Alexandersen<sup>6</sup>. The prevalence of these three-rooted mandibular first molars appears to be less than 3% in African populations, not to exceed 4.2% in Caucasians<sup>7</sup>, to be less than 5% in Eurasian and Asian populations<sup>8</sup>, and to be higher than 5% (even up to 40%) in populations with Mongolian traits<sup>9</sup>.

**Case report 1:**

A 33-year-old male came for endodontic treatment of mandibular right first molar. On clinical examination the tooth was grossly decayed on the buccal surface and was suffering from irreversible pulpitis. Radiograph of mandibular right first molar was normal without any periapical changes (Fig 1). After anaesthetizing the tooth, access preparation

was done under rubber dam with endo-access bur and canal orifices were located with DG 16 endodontic explorer. Initial negotiation of the root canals was conformed with K-file 15. The fourth disto-lingual canal orifice was present somewhere between the mesial and distal root canal orifices, more nearer to distal orifice.

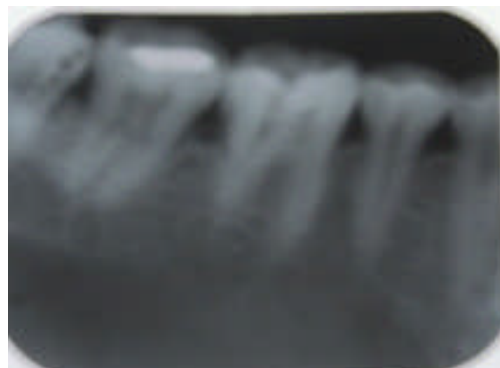
The canal lengths were determined radiographically with K file ISO 15 size and electronically with Root ZX. They were cleaned with 2.5% sodium hypochlorite and shaped with protaper rotary system till a size of F-2 (fig.2), calcium hydroxide intra canal medicament was given and patient was recalled after 1 week. At next appointment patient was asymptomatic and canals were dry enough to obturate. Master cone radiograph revealed proper fitting of cones (Fig.3). Obturation with cold lateral condensation technique using 2% gutta percha points and zinc oxide eugenol sealer was done (Fig 4). The access restoration was done with Fuji IX glass ionomer

**Case report 2**

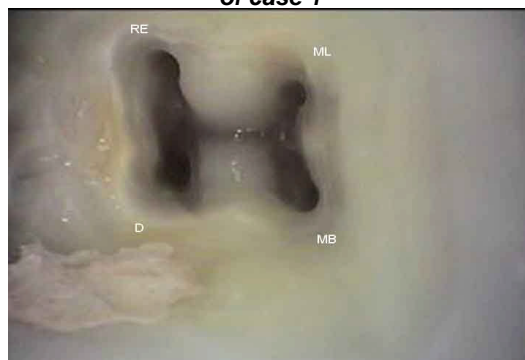
A 37 year old came for endodontic treatment of mandibular right first molar. On clinical examination the tooth was grossly decayed and had a distal and occlusal amalgam restorations which got failed and patient was symptomatic for cold and heat. Radiograph revealed gross carious lesion on distal surface involving the pulp space and also the presence of a third root between the mesial and distal roots (Fig. 5).

Access preparation was done with endo-access bur and canal orifices were located with DG 16 endodontic explorer. Initial negotiation of the root canals was performed with K-file 10. The fourth canal was present mesiobuccal to the distal orifice.

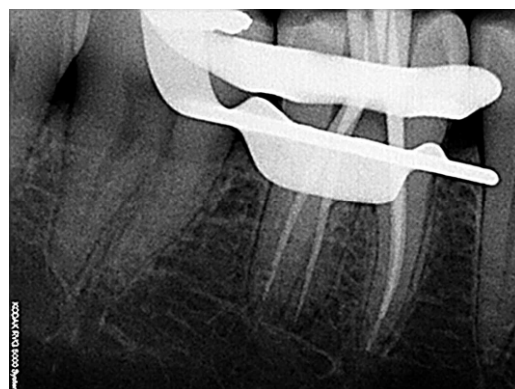The canal lengths were determined radiographically and electronically with K file ISO 15 size (Fig. 6). They were cleaned with 2.5% sodium hypochlorite and shaped with RACE rotary system and obturated with 4% gutta percha points and zinc oxide eugenol



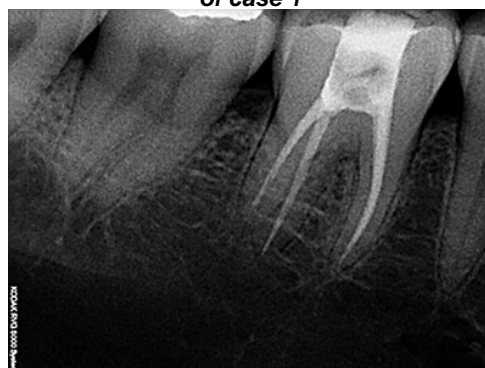**Fig. 1 – pre operative radiograph of case 1**



**Fig. 2 -Picture showing canal orifice of case 1**



**Fig.3-Radiograph showing master cone of case 1**



**Fig. 4 - Radiograph showing obturation of case 1**

sealer (Fig.7). The access restoration was done with IRM.

### Discussion

Radix entomolaris/paramolaris can be found on the first, second and third mandibular molar, occurring least frequently on the second molar. Bolk<sup>9</sup> reported the occurrence of a buccally located additional root: the RP. This macrostructure is very rare and occurs less frequently than the RE. The prevalence of RP, as observed by Visser<sup>10</sup>, was found to be 0% for the first mandibular molar, 0.5% for the second and 2% for the third molar.

The etiology behind the formation of RE is still unclear. In dysmorphic, supernumerary roots, its formation could be related to external factors during odontogenesis, or to penetrance of an atavistic gene or polygenetic system (atavism is the reappearance of a trait after several generations of absence).

### Morphology of the Radix Entomolaris and Paramolaris

A classification by Carlsen and Alexandersen<sup>6</sup> describes four different types of radix entomolaris according to the location of the cervical part of the RE: types A, B, C and AC. Types A and B refer to a distally located cervical part of the RE with two normal and one normal distal root components, respectively. Type C refers to a mesially located cervical part, while type AC refers to a central location, between the distal and mesial root components. This classification allows for the identification of separate and non-separate RE.

De Moor et al<sup>11</sup> classified RE based on the curvature in bucco-lingual orientation into three types. Type I refers to straight root or canal. Type II refers to an initially curved entrance which continues as a straight root/root canal. Type III refers to an initial curve in the coronal third of the root canal and a second curve beginning in the middle and continuing to the apical third. In the first case report the RE was present between the mesial and distal roots cervically and was straight in morphology.

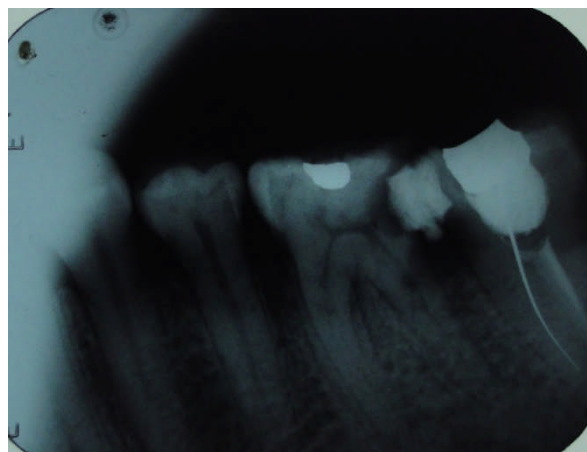


Fig. 5 - pre operative radiograph of case 2

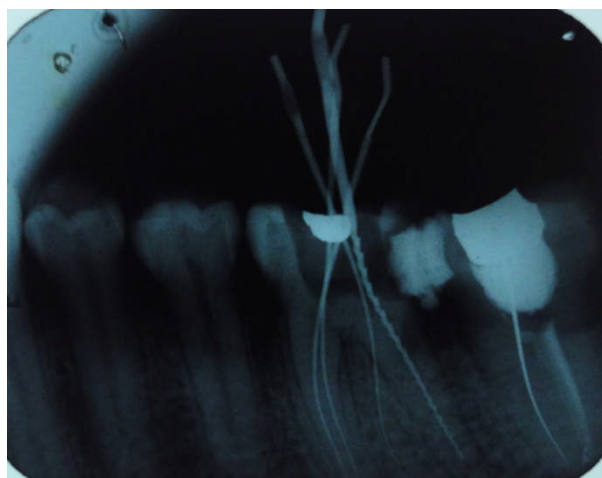


Fig. 6 - Radiograph showing working length of case 2

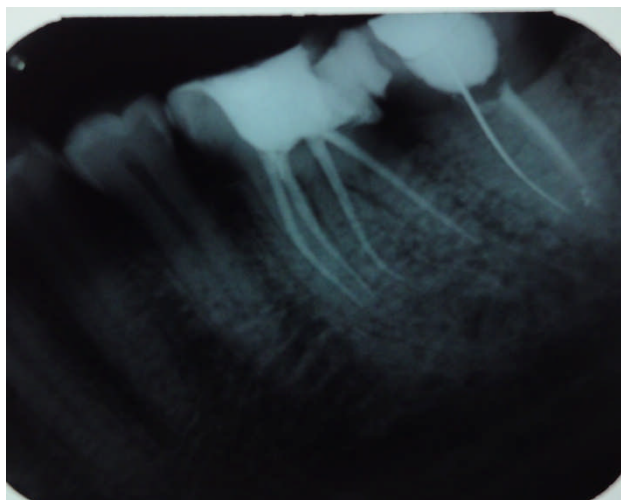


Fig. 7 - radiograph showing obturation of case 2

So it is a type AC and a type I radix entomolaris.

Carlsen and Alexandesen<sup>6</sup> described two different types of radix paramolaris. Type A refers to an RP in which the cervical part is located on the mesial root complex and type B refers to an RP in which the cervical part is located centrally between the mesial and distal root complexes.

### **Clinical approach**

The presence of and RE or an RP has clinical implications in endodontic treatment. The (separate) RE is mostly situated in the same buccolingual plane as the distobuccal root, and resultant superimposition of both roots can appear on the preoperative radiograph, resulting in an inaccurate diagnosis. A thorough inspection of the preoperative radiograph and interpretation of particular marks or characteristics, such as an unclear view or outline of the distal root contour or the root canal, can indicate the presence of a 'hidden' RE. To reveal the RE, a second radiograph should be taken from a more mesial or distal angle (30 degrees).

Clinical inspection of the tooth crown and analysis of the cervical morphology of the roots by means of periodontal probing can facilitate identification of an additional root. An extra cusp (tuberculum paramolare) or more prominent occlusal distal or distolingual lobe, in combination with a cervical prominence or convexity, can indicate the presence of an additional root. If an RE or RP is diagnosed before endodontic treatment, one knows what to expect or where to look once the pulp chamber has been opened.

The orifice of the RE is located disto-to mesio-lingually from the main canal or canals in the distal root. An extension of the triangular opening cavity to the (disto) lingual results in a more rectangular or trapezoidal outline form. If the RE canal entrance is not clearly visible after removal of the pulp chamber roof, a more thorough inspection of the pulp chamber floor and wall, especially in the distolingual region, is

necessary. Visual aids such as a loupe, intra-oral camera or dental microscope can, in this respect, be useful. A dark line on the pulp chamber floor can indicate the precise location of the RE canal orifice. The distal and lingual pulp chamber wall can be explored with DG 16 explorer to reveal overlying dentin or pulp roof remnants masking the root canal entrance. The calcification, which is often situated above the orifice of the RE, has to be removed for a better view and access to the RE. However, care should be taken not to remove an excessive amount of dentin on the lingual side of the cavity and orifice of the RE.

A severe root inclination or canal curvature, particularly, in the apical third of the root (as in a type III RE), can cause shaping aberrations such as straightening of the root canal or a ledge, with root canal transportation and loss of working length resulting. The use of flexible nickel-titanium rotary files allows a more centered preparation shape with restricted enlargement of the coronal canal third and orifice relocation. Therefore, after relocation and enlargement of the orifice of the RE initial root canal exploration with small files (size 10 or less) together with radiographical and electronic root canal length determination, and the creation of a glide path before preparation, are step-by-step actions that should be taken to avoid procedural errors.

### **CONCLUSION**

Endodontists must be aware of normal and abnormal root morphologies of tooth. An accurate diagnosis of these supernumerary roots can avoid complications that arise during canal negotiation and enlargement like fracture of endodontic instruments in canals, perforations or of a 'missed canal' during root canal treatment. Two pre-operative periapical radiographs, one exposed straight another at 20° horizontal angles are required to identify these additional roots enabling a modified opening cavity preparation with extension to the distolingual. The possibility of an extra root should also be considered and looked for

carefully. Proper knowledge of law of symmetry and law of orifice location, angulation and interpretation of radiographs, tactile sensation with hand instruments, performing Champagne effect- while using sodium hypochlorite in pulp chamber and utilizing the best of magnification aids like loupes and dental operating microscopes help to identify these abnormal root anomalies and to adapt a better clinical approach to avoid or overcome procedural errors during endodontic therapy.

### References

1. Barker BC, Parson KC, Mills PR, Williams GL. Anatomy of root canals in permanent mandibular molars. *Aust Dent J* 1974;19:403–13.
2. Vertucci FJ. Root canal anatomy of the human permanent teeth. *Oral Surg Oral Med Oral Pathol* 1984;58:589 – 99.
3. Thoden Van Veizen SK, Wesselink PR, De Cleen MJH. *Endodontology*, 2nd ed. Bohn Stafleu Van Loghum, Houtem/Diegem, 1995;142 – 3.
4. Fabra-Campos H. Unusual root anatomy of mandibular first molars. *J Endod* 1989;11;568– 57.
5. Carabelli G. *Systematisches Handbuch der Zahnheilkunde*, 2nd ed. Vienna: Braumuller und Seidel, 1844:114.
6. Carlsen O, Alexandersen V. Radix paramolaris in permanent mandibular molars identification and morphology. *Scan J Dent Res* 1991;99: 189– 95.
7. Curzon MEJ, Curzon AJ. Three-rotated mandibular molars in the Keewatin Eskimo. *J can Dent Assoc* 1971;37:71 – 2.
8. Yew SC, Chan K. A retrospective study of endodontically treated mandibular first molars in a Chinese population. *J Endod* 1993;19: 471 – 3.
9. Bolk I. Welcher Gebreihe gehören die Molaren an? *Z Morphol Anthropol.* 1914;17:83 – 116.
10. Visser JB. Beitrag zur Kenntnis der menschlichen Zahnwurzelformen. *Hilversum: Rotting* 1948;49 – 72.
11. De Moor RJ, Deroose CA, Calbertson FL. The radix entomolaris in mandibular first molars: an endodontic challenge. *Int. Endod J* 2004;37:789 – 99.

### Corresponding Author :

**Dr.T. Ram Babu. M. D. S.,**  
Professor  
Department of Conservative Dentistry &  
Endodontics,  
Vishu Dental College, Bhimavaram,  
Andhra Pradesh, India.  
Ph: 91-944-036-4064  
Email: [dr Rambabu@rediffmail.com](mailto:dr Rambabu@rediffmail.com)