

ENDODONTIC MANAGEMENT OF MAXILLARY MOLAR WITH SIX ROOT CANALS - A CASE REPORT

¹ Sirisha Gundam ¹ Senior lecturer

¹ Department of Conservative Dentistry and Endodontics, Narayana Dental College, Nellore, Andhra Pradesh.

ABSTRACT: The aim of the present case report is to describe the unusual root canal anatomy of maxillary first molar with six canals, three in mesiobuccal root, two in distobuccal root and one in palatal root. This article highlights the importance of modifying the access opening and magnification in location of the additional canal orifices.

KEYWORDS: Maxillary Molar, Mesiobuccal, Distobuccal, Dental Operating Microscope

INTRODUCTION

Thorough knowledge of root canal morphology and its frequent variations are the prerequisite for successful endodontic therapy. Inability to locate, clean and obturate a root canal has been shown to be a major cause of failure in endodontic therapy. According to Hoen and Pink, incidence of missed roots or root canals is 42% in the teeth that required retreatment. Therefore, it is of utmost importance that all the canals be located and treated during endodontic therapy.¹

Permanent maxillary first molar shows a wide variation in regard to number of root canals ranging from two to eight canals. Very few authors have documented six canals in maxillary first molars. Martinez-Berna and Ruiz-Badanelli reported three cases of maxillary first molars with six canals: 3 canals in the mesiobuccal root (MB), 2 in the distobuccal root (DB), and 1 in the palatal root.² Bond, Albuquerque, Karthikeyan et al. has also reported cases with six canals in the maxillary first molar with two canals in each root.^{3, 4, 5} Kottor et al. documented two cases with seven and eight canals in maxillary molar.^{6, 7}

Clinically when newer instruments, equipment like operating microscope, ultrasonic tips were employed, an increase in the number of extra canals was demonstrated.⁸

The present case reports the successful management of an unusual maxillary molar with six canals, three in mesiobuccal root, two in distobuccal root and one in palatal root.

Case report

A 28-year-old male patient reported to our department of Conservative Dentistry and Endodontics with a complaint of severe pain in the left upper back tooth region since two days. He gave a history of intermittent pain for the past 3 months, which had increased in intensity in the

past 2 days. Clinical examination revealed a deep carious lesion in left maxillary first molar which was tender on percussion. Thermal and electrical pulp testing elicited a negative response in the left maxillary first molar. A diagnosis of acute apical periodontitis was made and endodontic treatment was initiated. Tooth was anesthetized (2% lignocaine) and under rubber dam isolation, conventional access opening was made.

Clinical examination of the pulp chamber revealed 3 principal root canals: MB, DB, and palatal. Careful probing of the pulp chamber revealed a second mesiobuccal canal slightly lingual to the main canal (MB2). The access opening was modified to wider trapezoidal form. Upon further exploration under operating microscope (Seiler, Seiler Instruments & Manufacturing Company, Inc, St Louis, MO), a third canal in mesial root (MB3) and second canal in distobuccal root (DB2) were revealed (**Fig. 1**). A small amount of dentin that was occluding the orifice of the third mesiobuccal canal was removed. Working lengths were determined using an Apexlocator (Root ZX, J. Morita USA), and a radiograph was taken to confirm the working length. The working length radiograph confirmed the presence of all six canals in the tooth (MB1, MB2, MB3, DB1, DB2, P). The MB2 and MB3 joined in the apical third. The two distobuccal canals joined in the middle third and exited as single canal (**Fig. 2**).

The canals were irrigated thoroughly with 3% NaOCl (Pyrex export, Roorke, India). Biomechanical preparation was done with Protaper rotary instruments (Dentsply, Mallefer) in Crown Down technique and Calcium Hydroxide intracanal medicament (Prime Dental Pvt Ltd) was placed in the canals and the tooth was temporized. In the subsequent appointment, the patient was asymptomatic. Obturation was done with Endomethasone sealer (Septodont) and Guttaapercha (Dentsply, Mallefer). A post-obturation radiograph was obtained (**Fig. 3**).

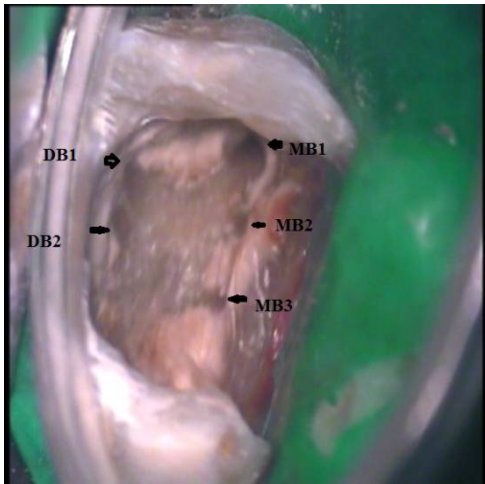


Fig.1. Access cavity showing 6 orifices (MB1, MB2, MB3, DB1, DB2, P)

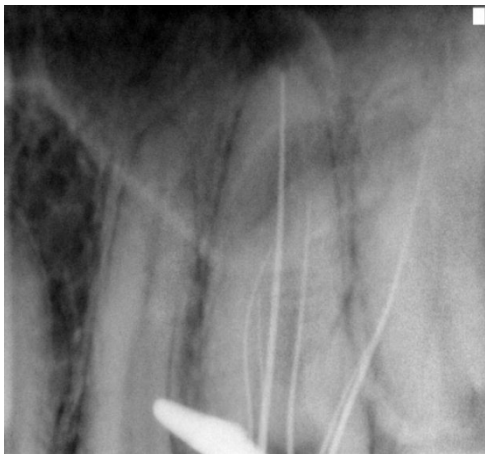

Fig .2 working length radiograph showing 6 canals

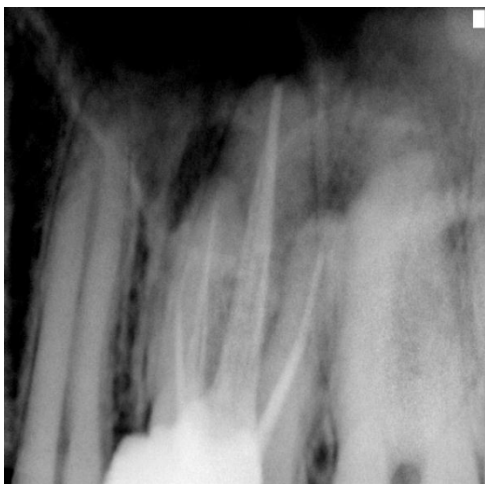

Fig. 3 Post obturation radiograph

Discussion

The complete removal of vital and necrotic remnants of pulp tissues, microorganisms, and microbial toxins from the root canal system is crucial for successful endodontic therapy. It is largely acknowledged that a major cause of failure of root canal treatment is the inability to recognize and therefore adequately treat all of the canals of the root canal system.^{9,10}

In literature, the maxillary first molar has been investigated more than any other tooth. Kulild and Peters conducted an *in vitro* study on 51 maxillary permanent molars and recorded the presence of MB2 canal in 96.1% of the teeth.¹¹ Few case reports documented the presence of a third canal in the mesio-buccal root. Two *in vitro* studies have reported their incidence to be between 1.1% and 10%.^{12,13}

In 93.3% of the times, the disto-buccal root canal system presents with a single canal. In almost all the studies which reported two disto-buccal canals, they exited as single canal at the apex. The incidence of two canals in disto-buccal root is rare, ranging from 1.64%- 9.5% in maxillary molars.¹⁴

Fogele *et al* reported that 71.2% of the teeth had their MB2 canals negotiated, from which 31.7% showed two distinct foramens with the use of magnification, proper illumination and modified access.¹⁵ Studies confirmed the increased canal location rate may be because of the improved knowledge of the internal morphology, modification of the access opening shape and use of the operating microscope.¹⁶ In an *in vivo* study by Buhre *et al*, the surgical operating microscope and dental loupes enhanced the ability of endodontists to locate mesiolingual canals in maxillary molars.¹⁷

A proper and adequate access opening is crucial for successful endodontic management. In the present case, the third MB canal was located by modifying the access cavity from the traditional triangular outline form to a trapezoidal shape which permitted straight line visualization, allowing for complete debridement of the pulp chamber.

In the present case, success was largely dependent on the use of magnification which greatly aided in localisation of the MB2, MB3 and DB2 canal orifices in the maxillary first molar with relative ease. Extensive knowledge of the morphology of the teeth, and careful examination under a microscope can help clinicians to recognize anatomical variations.

This case report stresses the importance of locating and treating the additional aberrant canals for positive outcome of the treatment.

CONCLUSION

This case report presents successful management of an unusual maxillary first molar with a six root canals. Thorough knowledge of the intricacies of the root canal system and recognising the importance of modified access preparations and magnification facilitate the detection and location of additional canals

References

1. Hoen MM, Pink FE. Contemporary endodontic retreatments: an analysis based on clinical treatment findings. *J Endod* 2002; 28: 834–6. <http://dx.doi.org/10.1097/00004770-200212000-00010>
2. Martinez-Bernla A, Ruiz-Badanelli P. Maxillary first molars with six canals. *J Endod* 1983;9: 375–8. [http://dx.doi.org/10.1016/S0099-2399\(83\)80188-5](http://dx.doi.org/10.1016/S0099-2399(83)80188-5)
3. Bond JL, Hartwell G, Portell FR. Maxillary first molar with six canals. *J Endod* 1988; 14: 258–60. [http://dx.doi.org/10.1016/S0099-2399\(88\)80180-8](http://dx.doi.org/10.1016/S0099-2399(88)80180-8)
4. Albuquerque DV, Kottoor J, Dham S, et al. Endodontic management of maxillary permanent first molar with 6 root canals: 3 case reports. *Oral Surg Oral Med Oral Pathol Oral RadiolEndod* 2010; 110: 79–83. <http://dx.doi.org/10.1016/j.tripleo.2010.04.017>
5. Karthikeyan K, Mahalaxmi S. New nomenclature for extra canals based on four reported cases of maxillary first molars with six canals. *J Endod* 2010; 36: 1073–8. <http://dx.doi.org/10.1016/j.joen.2009.12.001>
6. Kottoor J, Velmurugan N, Sudha R, et al. Maxillary first molar with seven root canals diagnosed with cone-beam computed tomography scanning: a case report. *J Endod* 2010;36:915–21 <http://dx.doi.org/10.1016/j.joen.2009.12.015>
7. Jojo Kottoor, Natanasabapathy Velmurugan, Smitha Surendran. Endodontic Management of a Maxillary First Molar with Eight Root Canal Systems Evaluated Using Cone-beam Computed Tomography Scanning: A Case Report. *J Endod* 2011;37:715–719. <http://dx.doi.org/10.1016/j.joen.2011.01.008>
8. Vertucci FJ. Root canal morphology and its relationship to endodontic procedures. *Endod Topics* 2005;10:3–29. <http://dx.doi.org/10.1111/j.1601-1546.2005.00129.x>
9. Weine FS, Healey HJ, Gerstein H, Evanson L. Canal configuration in the mesiobuccal root of the maxillary first molar and its endodontic significance. *Oral Surg* 1969;28: 419 –25. [http://dx.doi.org/10.1016/0030-4220\(69\)90237-0](http://dx.doi.org/10.1016/0030-4220(69)90237-0)
10. Vertucci FJ. Root canal anatomy of the human permanent teeth. *Oral Surg Oral Med Oral Pathol Oral RadiolEndod* 1984; 58: 589–99. [http://dx.doi.org/10.1016/0030-4220\(84\)90085-9](http://dx.doi.org/10.1016/0030-4220(84)90085-9)
11. Kulild JC, Peters DD. Incidence and configuration of canal systems in the mesiobuccal root of maxillary first and second molars. *J Endod* 1990; 16: 311–7. [http://dx.doi.org/10.1016/S0099-2399\(06\)81940-0](http://dx.doi.org/10.1016/S0099-2399(06)81940-0)
12. Verma P, Love RM. A micro CT study of the mesiobuccal root canal morphology of the maxillary first molar tooth. *IntEndod J* 2011; 44: 210–7. <http://dx.doi.org/10.1111/j.1365-2591.2010.01800.x>
13. Degerness RA, Bowles WR. Dimension, anatomy and morphology of the mesiobuccal root canal system in maxillary molars. *J Endod* 2010; 36: 985–9 <http://dx.doi.org/10.1016/j.joen.2010.02.017>
14. Cleghorn, W. H. Christie, and C. C. S. Dong, "Root and root canal morphology of the human permanent maxillary first molar: a literature review," *J Endod* 2006, vol. 32 no. 9, pp. 813–820, 2006.
15. Fogel HM, Christie WH, Peikoff MD. Canal configuration in the mesiobuccal root of the maxillary first molar: a clinical study. *J Endod*. 1994 Mar;20(3):135-7. [http://dx.doi.org/10.1016/S0099-2399\(06\)80059-2](http://dx.doi.org/10.1016/S0099-2399(06)80059-2)
16. Imura N, Hata G, Toda T, Otani SM, Fagundes MIRC. Two canals in mesiobuccal roots of maxillary molars. *Int Endod J*. 1998 Nov;31(6):410-4
17. Burhley LJ, Barrows MJ, BeGole EA, Wenckus CS. Effect of magnification on locating the MB2 canal in maxillary molars. *J Endod* 2002;28:324 –7 <http://dx.doi.org/10.1097/00004770-200204000-00016>

Corresponding Author

Dr. Sirisha Gundam,
Flat no-105, 3-6-290/B,
Sai Tirumala Towers, Hyderguda,
Hyderabad-500029
Phone No.- 9849205785, 9553511157
Email : drsirisha222@yahoo.co.in