

DETERMINATION OF GENDER USING CONDYLAR HEIGHT AND CORONOID HEIGHT – AN ORTHOPANTOMOGRAPHIC STUDY

<sup>1</sup> Jyothsna M	<sup>1</sup> Associate Professor
<sup>2</sup> Ranjith K	<sup>2</sup> Post graduate Student
<sup>3</sup> Sarat G	<sup>3</sup> Professor
<sup>4</sup> Vajra Madhuri	<sup>4</sup> Associate professor
<sup>5</sup> Anuradha Ch	<sup>5</sup> Assistant Professor

<sup>1</sup> Department of Oral Pathology, <sup>4</sup> Department of Periodontics, <sup>5</sup> Department of Oral Medicine and Radiology, Government Dental College and Hospital, Vijayawada, Andhra Pradesh.  
<sup>2,3</sup> Department of Oral Medicine and Radiology, Drs Sudha and Nageswara Rao Siddhartha Institute of Dental Sciences, Chinnoutpally, Gannavaram, Vijayawada.

**ABSTRACT: BACKGROUND:** Identification of gender is important in forensic science and anthropology. When entire skull is not available for analysis, mandible may play a vital role in sex determination as it is the strongest bone that resists damage and disintegration. **Aims and Objectives:** To determine the efficacy of condylar height and coronoid height of mandible for sex determination using orthopantomographs and to compare and determine the most reliable parameter for sex determination. **Materials and methods:** This study was conducted using digital panoramic images of 100 each in both genders. The images captured were viewed on Kodak software and were subjected to measure the condylar and coronoid heights both on left and right side using Kodak dental imaging software. The data was entered into Microsoft Excel sheet and statistical analysis was done. **Results:** Descriptive statistics for condylar and coronoid heights on the right and left sides of mandible in both males and females were analyzed. A statistical significance of  $P < 0.001$  has been demonstrated for all the variables. All variables showed increased measurements in males than in females. The accuracy of sex determination for condylar height is 82.5% on right side and 78% on left side and for coronoid height it is 74% on right side and 73% on left side. **Conclusion:** The parameters such as condylar height and coronoid height using orthopantomographs are reliable in gender determination and the condylar height of the right side is the best parameter in gender determination.

**KEYWORDS:** Digital orthopantomogram; condylar height; coronoid height

INTRODUCTION

Every human has their own facial and external features which help in recognizing as a male or a female. The visual recognition and identification of an individual is difficult during natural disasters like earthquakes, tsunami like events, floods and man-made disasters such as transport accidents, bombings and other terrorist activities. In such conditions, a scientific technique is necessary for identification of a person. Such scientific or primary methods include comparison of fingerprint patterns, medical and dental evidence and analysis of deoxyribonucleic acid (DNA).<sup>1</sup>

Among human bones, the pelvis and skull are the most reliable source for gender determination. It is possible to determine gender and age quite readily from the remains, including the cranial structures and teeth. Evidence of personal habits are occasionally present in the dentition.<sup>2</sup> Gender of an unknown individual can be determined based on the data from the morphology and metric features of skull and mandible, soft tissues, as well as by DNA analysis of teeth.<sup>3</sup> Skull is the most dimorphic and easily sexed portion of skeleton after pelvis, providing

accuracy up to 92%.<sup>4</sup> But in cases where intact skull is not found, mandible may play a vital role in sex determination as it is the most dimorphic, largest, strongest and mobile bone of skull.<sup>5,6</sup> Presence of a dense layer of compact bone makes it very durable, and hence remains well preserved than many other bones. Dimorphism in mandible is reflected in its shape and size.<sup>7</sup> Its morphological features show changes with reference to age, sex and race. Male bones are generally bigger and more robust than female bones. Greatest morphological changes showing the sexual dimorphism in the mandible are particularly seen in the mandibular condyle and ramus than the body of the mandible.<sup>8</sup>

Panoramic radiography is a simplified extraoral radiographic technique which visualizes the entire maxillo-mandibular region, temporo-mandibular joints and associated structures on a single film which gives a panoramic or bird's eye view of the jaws.<sup>9</sup> Panoramic imaging has become a popular and important diagnostic tool since its introduction in the 1950s. It is being used for

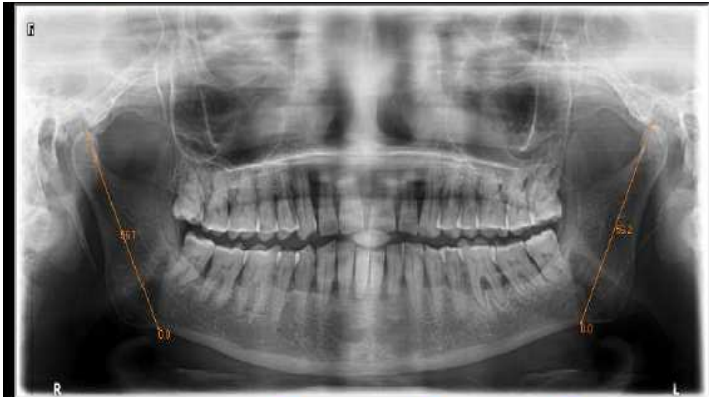

Fig. 1: Panoramic image showing measurement for condylar height in Kodak dental imaging software

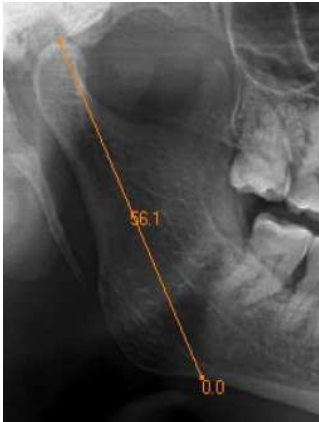

Fig. 2: Cropped panoramic image showing measurement for condylar height

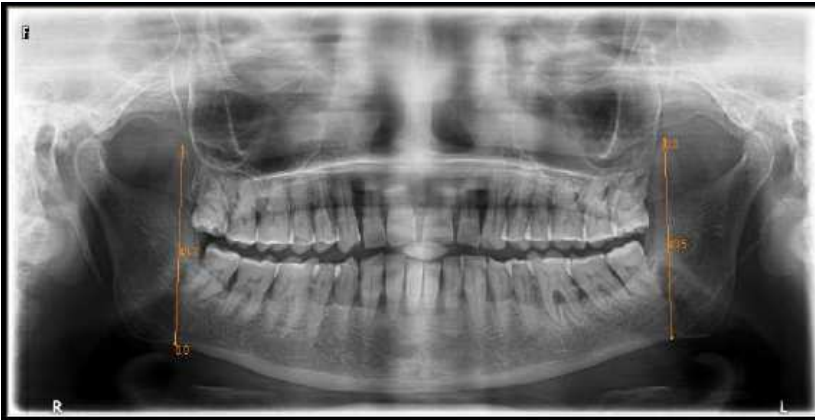

Fig. 3: Panoramic image showing measurement for coronoid height in Kodak dental imaging software

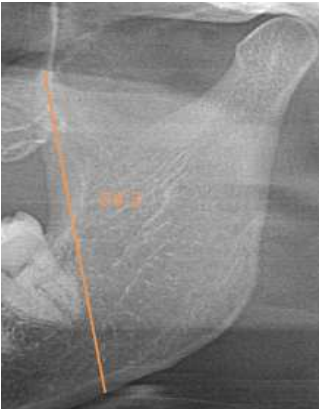


Fig.4: Cropped panoramic image showing measurement for coronoid height

routine screening of patients at various institutions and private clinics.<sup>10</sup>

Considering these advances, the present study aims to assess the accuracy of sex determination using condylar height and coronoid height with ortho-pantomographs of known age and sex individuals.

**Aims and objectives**

A total of 200 patients were included in the study. Orthopantomographs were taken for these patients to calculate condylar height and coronoid height.

1. To determine the efficacy of condylar height of mandible for sex determination using orthopantomographs.

2. To determine the efficacy of coronoid height of mandible for sex determination using ortho - pantomographs.
3. To compare and determine the most reliable parameter for sex determination.

**Materials and methods**

**Source of the data:**

The study sample comprised of patients reporting to the outpatient department with routine dental problems. The patients were provided a detailed background of the intended procedure and enquiry was made about their willingness to participate in the study. Only those patients who gave consent to take part in the study were included.

Inclusion criteria:

Patients in the age group of 20 to 60 years of both the genders were included in the study. Ideal orthopantomographs of patients with complete dentition were considered.

Exclusion criteria:

Subjects who exhibited developmental disturbances, deformities, fractures or pathologies involving the mandible on clinical or radiographic examination were not considered for inclusion in the sample.

**Sample distribution:** A Total of 200 subjects aged 20-60 years were divided into 2 groups. Group I includes 100 female subjects and group II includes 100 male subjects.

Technique of radiography:

**Procedure:** The subject was seated comfortably in the dental chair and his/her oral cavity was thoroughly examined with special attention to rule out the conditions mentioned in the exclusion criteria. Subjects having all the maxillary and mandibular teeth were selected. Jewellery and other artefact-causing objects were removed; for example nose rings, ear rings, chain, eye glasses etc. The patient's identification number, sex and date were recorded.

The exposure parameters were set according to the patient's size. The patient was positioned and the image was taken. The digital images captured were viewed on Kodak software and measurements were recorded. Images that are properly exposed with no errors and high image clarity were chosen for the study. The orthopantomogram images were subjected to measurements using Kodak dental imaging software.

Method for measuring the parameters:

To ensure the accuracy and the reproducibility of the technique, reference points were made on the orthopantomogram for measuring the parameters given below.

**Condylar height:**Height of the ramus of the mandible from the most superior point on the mandibular condyle to the tubercle, or most protruding portion of the inferior border of the ramus.

**Coronoid height:** Distance from coroniod to the most protruding portion of the inferior border of the ramus.

Results

The study included a total sample of 200 subjects having all maxillary teeth, mandibular teeth for whom orthopantomographs were taken. They are divided into

two groups based on the sex. Group I included total of 100 females with the age range of 20 to 60 years. Group II included total of 100 males with age range of 20 to 60 years. Age and sex distribution of individuals are listed in **Table 1.**

Table 1. Demographic information of the sample

Group	Age range	sex		Total
		Male	Female	
Group I	20 – 60	0	100	100
Group II	20 – 60	100	0	100

Statistical analysis

Data were entered in MS EXCEL and analyzed in SPSS V22. Descriptive statistics were represented in the form of Mean and SD. t-test was applied to find the significance. P<0.05 was considered as statistically significant. Binary logistic regression was fitted to estimate the gender. Cutt-off values were calculated.

The mean right condylar height was 61.32 in females, whereas in males it was 68.04. The mean right condylar height between male and female was showing statistical significance. **(Table – 2)**

The mean left condylar height was 61.74 in females and in males it was 67.74. left condylar height between male and female was showing statistical significance. **(Table – 3)**

The mean right coronoid height was 52.79 in females, whereas in males it was 58.33. The mean right coronoid height between male and female was showing statistical significance. **(Table – 4)**

The mean left coronoid height was 52.78 in females, whereas in males it was 58.48. The mean left coronoid height between male and female was showing statistical significance. **(Table – 5)**

The Cutt-off value of right condylar height was 64.56 and 82.5% of the subject's gender was predicted correctly by using right condylar height variable. **(Table – 6)** and

The Cutt-off value of left condylar height was 64.69. 78% of the subject's gender was predicted correctly by using left condylar height variable. **(Table – 7)**

The Cutt-off value of right coronoid height was 55.43. 74% of the subject's gender was predicted correctly by using right coronoid height variable.**(Table – 8)**

The Cutt-off value of left coronoid height was 55.44. 73% of the subject's gender was predicted correctly by using left coronoid height variable.**(Table – 9)**

Discussion

Sex determination is one of the important hallmarks in the forensic analysis and anthropology. The morphological, metrical and biochemical methods have been used in determining sex. The morphological methods have some drawbacks because of inter-examiner variability. The biochemical methods are complicated and expensive. The advantage of the metrical parameters is that they can be reproducible and the errors can also be less between the observers.<sup>3</sup>

The mandible is the strongest bone in the human body and persists in well preserved state longer than any bone. The different genetic predisposition in males and females during development is responsible for the sexual dimorphism. Males also have a larger muscle mass that apply greater mechanical forces on the mandible compared to that in females. Young and adult human males have a significantly larger bite forces than females which could be attributed to the larger muscle mass in males. An increased muscle mass affects the facial morphology and thus the differential muscle mass in males and females as a result of genetics could contribute to the sexual dimorphism. This could be an important differentiating factor that causes sexual dimorphism. The large muscle mass of the temporalis may explain the elongated coronoid process in the mandibular morphology of males.<sup>11</sup>

The accuracy of panoramic radiography in providing anatomic measurements has been recognized. The main advantages of panoramic images are their broad coverage, low radiation dose, and less time required for image acquisition. Furthermore, the contrast and brightness enhancement and enlargement of images provide an accurate and reproducible method of measuring the chosen points. The limitations of this technique are magnification and geometric distortion, however, the vertical dimension in contrast to the horizontal dimension is altered less. Panoramic radiographic technique remains as quite sensitive to positioning errors because of relatively narrow image layer.<sup>12</sup>

In the present study a total of 200 ideal orthopantomographs were included in the age range of 20 to 60 years which corresponded to 100 males and 100 females having a complete set of natural teeth excluding the presence or absence of the third molar. The measurements of the condylar height and coronoid height, were measured using Kodak dental imaging software. The measurements were analyzed with SPSS software version 22.

The maximum condylar height in females on the right side in this study is 70.9mm and the minimum condylar height is 51.8mm with a mean of 61.32 ± 3.54mm. The maximum and minimum condylar height in males is 77.6mm and 56.5mm and the mean condylar height on the right side is 68.04 ± 4.20mm (**Table 2**). The

role of condylar height of right side is found to be highly significant in gender determination. The mean condylar height of left side in females is found to be 61.74 ± 3.74mm with a maximum condylar height of 69.7mm and a minimum height of 53.9mm whereas in males the mean condylar height of left side is 67.74 ± 4.34mm with maximum and minimum condylar height as 77.7mm and 56.5mm respectively(**Table 3**). The left condylar height was also found to be highly significant in gender determination.

In a study done by Rinkiet al.<sup>13</sup> on orthopantomographs they found that the condylar height was found to be statistically highly significant and the mean value in males and females are 66.78 ± 5.47 mm and 59.99 ± 5.07 mm which was almost similar to that of the present study. Similar findings were noticed in a study done by Sairamet al.<sup>14</sup> comparing the different mandibular measurements the condylar height was found to be significant in gender determination with mean in males and females being 65.01mm and 59.48mm on right side and 65.71mm and 59.65mm on left side. The present study has shown the similar results to that of a study done by Samatha K et al.<sup>15</sup> the condylar height was found to be significant and the mean value for males is 65.34mm and females is 61.69mm. In a study done by Saraswathi G et al.<sup>16</sup> on CBCT images of 50 male and 50 female patients the mean condylar height is found to be 65.79mm in males and 61.80mm in females. These findings conclude that the height of the condyle can be the best parameter.

The maximum coronoid height in females on the right side is found to be 61.9mm with a minimum height of 42.8mm. The mean coronoid height in females is found to be 52.79 ±3.97mm and in males, the maximum and minimum coronoid height is found to be 69.2mm and 47.0mm with a mean value of 58.33 ± 4.77 mm (**Table 4**). The coronoid height of the right side also showed a statistically significant difference in determining sex. The maximum coronoid height on the left side is 62.0 mm in females and 69.4 mm in males. The minimum coronoid height is 42.5 mm in females and 47.2 mm in males respectively (**Table 5**). The mean coronoid height is 52.78 ± 3.92 mm in females which is lesser than that of males 58.48 ± 5.13 mm and is found to be statistically significant in determination of gender.

The similar results were obtained in a study done on orthopantomographs by Rinki et al.<sup>13</sup> with a mean value of coronoid height in males and females is 62.28 ± 5.41 mm and 56.88 ± 4.80 mm which was found to be highly significant. The similar findings were obtained in a study done by Sairamet al.<sup>14</sup> comparing the different mandibular measurements in which the coronoid height was found to be significant in gender determination with mean in males and females is 57.61mm and 53.15mm on right side and 58.52mm and 53.40mm on left side. In a study done by Samatha K et al.<sup>15</sup> the coronoid height was found to be non-significant and mean score for males is 57.85mm and 55mm in females which was in contrast to the present

Table 2: Comparison of condylar height of right side with gender

Variable	Sex	N	Minimum	Maximum	Mean	SD	t-value	P-value
Condylar height –right	Female	00	51.8	70.9	61.32	3.54	12.23	<0.001
	Male	00	56.5	77.6	68.04	4.20		

Table 3: Comparison of condylar height of left side with gender

Variable	Sex	N	Minimum	Maximum	Mean	SD	t-value	P-value
Condylar height –Left	Female	100	53.9	69.7	61.74	3.74	10.46	<0.001
	Male	100	56.5	77.7	67.74	4.34		

Table 4: Comparison of coronoid height of right side with gender

Variable	Sex	N	Minimum	Maximum	Mean	SD	t-value	P-value
Coronoid height –Right	Female	100	42.8	61.9	52.79	3.97	8.93	<0.001
	Male	100	47.0	69.2	58.33	4.77		

Table 5: Comparison of coronoid height of right side with gender

Variable	Sex	N	Minimum	Maximum	Mean	SD	t-value	P-value
Coronoid height –Left	Female	100	42.5	62.0	52.78	3.92	8.83	<0.001
	Male	100	47.2	69.4	58.48	5.13		

Table – 6 Comparison of prediction percentage of right condylar height with gender

Condylar height –right			
Original	Predicted		Percentage Correct
	Female	Male	
Female	82	18	82
Male	17	83	83
Overall predicted correct %			82.5

Table – 7 Comparison of prediction percentage of left condylar height with gender

Condylar height –left			
Original	Predicted		Percentage Correct
	Female	Male	
Female	77	23	77
Male	21	79	79
Overall predicted correct %			78

Table – 8. Comparison of prediction percentage of right coronoid height with gender

Coronoid height –right			
Original	Predicted		Percentage Correct
	Female	Male	
Female	76	24	76
Male	28	72	72
Overall predicted correct %			74

Table – 9. Comparison of prediction percentage of left coronoid height with gender

Coronoid height –left			
Original	Predicted		Percentage Correct
	Female	Male	
Female	79	21	79
Male	33	67	67
Overall predicted correct %			73

study. In a study done by Saraswathi Get al.<sup>16</sup> on CBCT images of 50 male and 50 female patients, the mean coronoid height is found to be 59.37mm in males and 56.40mm in females which was similar to the results of the present study.

The limitation of the study is that it would have been better if the present study used CBCT as there is less distortion and artifacts but was not considered as the radiation dose to the patient is high. The relation between age group and gender determination was not done in our study as the subjects with complete dentition have been considered for the study.

## CONCLUSION

Mandible can be considered as a beneficial tool in gender determination since it possesses resistance to damage and disintegration process. It is considered the second most sexually dimorphic bone after the pelvis. The orthopantomograph is widely used for obtaining a comprehensive overview of the maxillofacial complex. The parameters considered in the current study were condylar height, coronoid height of both sides. The measurements were done using Kodak dental imaging software. This study concluded that the parameters such as condylar height and coronoid height using orthopantomographs are reliable in gender determination and condylar height of the right side is the best parameter in gender determination.

## References

1. Akhilesh Chandra, Bastian TS, Anil Singh, Bhagirathi DL. Role of dentist in identification in mass disaster. *Ind J of Forensic Medicine Toxicology* 2010; 4(2): 1-5
2. Hu KS, Koh KS, Han SH, Shin KJ, Kim HJ. Sex determination using nonmetric characteristics of the mandible in Koreans. *J Forensic Sci.* 2006 Nov; 51(6):1376-82.
3. G. D'Eyrames, F. Siegmund & C. Papageorgopoulou. Discriminant function analysis versus morphognostic sex determination of 637 crania from the Poschiavo ossuary. *Bulletin der Schweizerischen Gesellschaft für Anthropologie.* 2009; 15 (1-2): 57-63.
4. Mohite DP, Chaudhary MS, Mohite PM, Patil SP. Age Assessment from mandible: comparison of radiographic and histological methods; *Rom J Morphol Embryol*, 2011; 52(2): 659-668.
5. Scheuer L. Application of osteology to forensic medicine. *Clin Anat*, 2002; 15: 297-312.
6. Saini V, Srivastava R, Rai RK, Shamal SN, Singh TB, Tripathi SK. Mandibular ramus; An indicator for sex in fragmentary mandible. *J Forensic Sci*, 2011; 56(Suppl1): S13-6.
7. Humphrey LT, Dean MC, Stringer CB. Morphological variation in great ape and modern human mandibles. *J Anat*, 1999; 195: 491-513.
8. Franklin D, O'Higgins P, Oxnard CE, Dadour . Discriminant function sexing of the mandible of Indigenous South Africans. *Forensic Sci Int*, 2008; 179: 84-5
9. Park TW, Lee SR, Kim JD, Park CS, Choi SC, Koh KJ, et al. *Oral and maxillofacial radiology*. 3rd ed. Seoul. Narae Publishing Inc. 2001. p. 138-45.
10. Rushton VE, Horner K, Worthington HV. Aspects of panoramic radiography in general dental practice. *Br Dent J* 1999; 186: 342-4.
11. Singh R, Mishra SR, Sushobhana, Passey J, Kumar P et al. Sexual dimorphism in adult human mandible of North Indian origin. 2015; 3: 82 – 88
12. Poongodi V, Kanmani R, Anandi MS, Krithika CL, Kannan A, and Raghuram PH. Prediction of age and gender using digital radiographic method: A retrospective study. *J Pharm Bioallied Sci.* 2015; 7(Suppl 2): S504-S508.
13. Rinki C, Leena R, Sushma KK, Anoop GS, Ritu A, Surbhi A. An orthopantomographic study for sex determination by mandibular ramus in western rajasthan population. *International Journal of Advanced Research and Review.* 1(7), 2016; 28-36.
14. Sairam V, Geethamalika MV, Kumar PB, Naresh G, Raju GP. Determination of sexual dimorphism in humans by measurements of mandible on digital panoramic radiograph. *Contemp Clin Dent* 2016; 7: 434-9.
15. Byahatti S, Samatha K, Ammanagi R, Tantradi P, Sarang C, Shivpuje P. Sex determination by mandibular ramus: A digital orthopantomographic study. *Journal of Forensic Dental Sciences.* 2016; 8(2): 95.
16. Saraswathi G, Kshatri JK, Mahesh K. Sex determination with mandibular ramus – a retrospective study based on cone beam computer tomography. *International journal of information research and review.* 2016; 3: 2328-2329.

## Corresponding Author

**Dr S. Vajra Madhuri**, M.D.S,  
Associate professor,  
Department of Periodontics,  
Government Dental College & Hospital,  
Vijayawada  
Email ID –madhuri.songa@gmail.com  
Mobile no – 9885333771