

CONE BEAM VOLUMETRIC TOMOGRAPHY (CBVT)- IN ORTHODONTICS

¹Preeti Bhardwaj ¹ Reader
² Lakshmayya Naidu ² Professor and Head, Principal
¹³ Anupam Agarwal ³ Senior lecturer

¹, Department of Orthodontics, K.D. Dental college and Hospital, Mathura, Uttar Pradesh, India.

², Lenora Dental College, Rajamundry, Andhra pradesh, India

³ Teerthanker Mahaveer Dental College and Research Centre, Moradabad (Uttar Pradesh),India.

ABSTRACT:

CBVT is being used in Orthodontics due its ability to obtain 3- dimensional representation of craniofacial structures. It represents a highly precise image of the anatomic structures and clearly depicts the location of various anatomic structures. The Cone beam volumetric tomography(CBVT) can be considered as an Essential Diagnostic Aid in patients having skeletal asymmetry and severe skeletal malocclusions undergoing Orthognathic surgeries.

KEYWORDS: CBVT, Orthognathic surgeries,Skeletal Malocclusion.

INTRODUCTION

The cone beam volumetric tomography (CBVT) is being increasingly used for the diagnosis and treatment planning in Orthodontics, Dentofacial Orthopedics and Orthognathics.¹ Recent advances in craniofacial imaging have made it possible to obtain 3-dimensional (3D) representations of the craniofacial structures with cone-beam computed tomography (CBCT). CBCT was first introduced to dentistry in the United States in 2000 at Loma Linda University.² Clinical Guidelines have been established for using CBCT in dentistry. These guidelines include the following applications in orthodontics: determining tooth position and localization, resorption related to impacted teeth, and bone dimensions for mini-implant placement; assessing airways; and investigating orthodontic-associated paresthesia. Orthodontists should use CBCT cautiously and always ask themselves whether the clinical question can be answered by conventional radiography³.

It presents a highly precise image of the anatomic structures and clearly depicts the location of various anatomic hazards, for example: neurovascular bundles, etc. It could be very problematic if the location of these anatomic hazards is missed during treatment planning. The measurements done on these CBCT images are highly accurate and can be correlated well with real time actual dimensions of the human anatomic structures and measurements from other imaging protocols.^{4,5,6,7}



Fig.1. Frontal

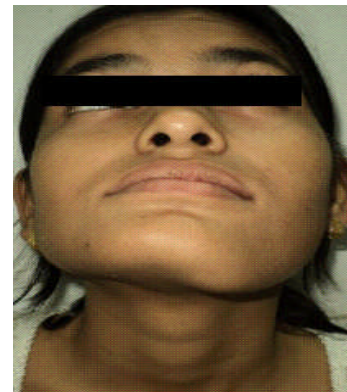

Fig.2. Sub-mental

Case Report

A female patient of 25 years reported with a chief complaint of facial asymmetry (Fig.1 and Fig.2.) to the Department of Orthodontics. Surgical correction of the facial asymmetry was the treatment planned. At the initial examination and consultation we considered a major reduction and reshaping of the inferior border of the mandible (on the left side). However, a routine CBCT examination revealed (Fig.3), to the surprise of the Orthodontist and the surgeon, that the neurovascular bundle traversing the body of the mandible (on the left side) was very close to the inferior border of mandible. This was the very anatomic site where surgical intervention was planned to be performed.

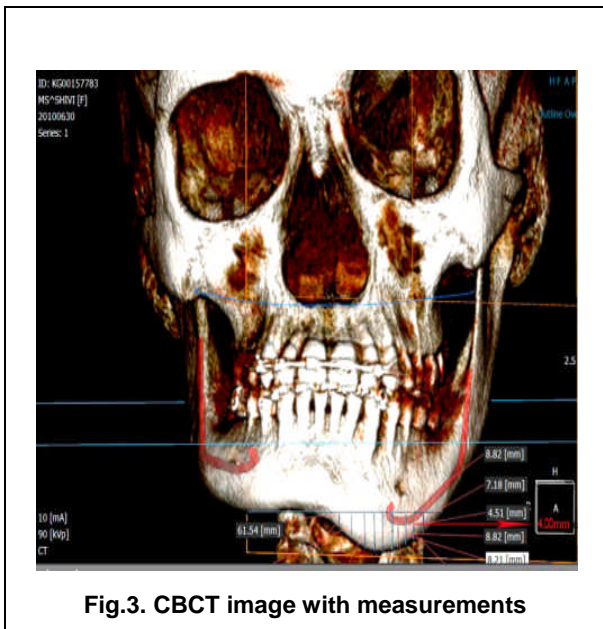


Fig.3. CBCT image with measurements

An imaging software “Kodak Dental Imaging Software 3D v2.2 (KDIS)” was used to precisely measure the linear distance of the neurovascular bundle from the inferior border of the mandible on the left side, on the CBCT image. The minimum distance was found to be 4.00mm.

The CBCT data and measurements led to the timely appraisal of the anatomic hazard in way of the planned treatment protocol. A highly conservative modified approach was thereby planned for the patient.

CONCLUSION

The authors recommend a cone beam computed tomography (CBCT) session for every patient undergoing Orthognathic surgical consultation. The Cone beam computed tomography (CBCT) can rightly be called an Essential Diagnostic Aid for Surgical Planning.

References

1. Lund H et al. Cone Beam Computed Tomography for Assessment of Root Length and Marginal Bone Level during Orthodontic Treatment. Angle Orthod. 2010;80:466–473. <http://dx.doi.org/10.2319/072909-427.1>
2. Mah J, Hatcher D. Three-dimensional craniofacial imaging. Am J Orthod Dentofacial Orthop 2004;126:308-9. <http://dx.doi.org/10.1016/j.ajodo.2004.06.024>
3. Turpin D.L. Clinical guidelines and the use of cone-beam computed tomography. Am J Orthod Dentofacial Orthop 2010;138:1-2. <http://dx.doi.org/10.1016/j.ajodo.2010.05.007>
4. Grauer D et al. Accuracy and Landmark Error Calculation Using Cone-Beam Computed Tomography–Generated Cephalograms. Angle Orthod 2010;80:286–294. <http://dx.doi.org/10.2319/030909-135.1>
5. Baumgaertel S et al. Reliability and accuracy of cone-beam computed tomography dental measurements. Am J Orthod Dentofacial Orthop 2009;136:19-28. <http://dx.doi.org/10.1016/j.ajodo.2007.09.016>
6. Halazonetis D.J et al. From 2-dimensional cephalograms to 3-dimensional computed tomography scans. Am J Orthod Dentofacial Orthop 2005;127:627-37. <http://dx.doi.org/10.1016/j.ajodo.2005.01.004>
7. Cattaneo P.M et al. Comparison between conventional and cone-beam computed tomography–generated cephalograms. Am J Orthod Dentofacial Orthop 2008;134:798-802. <http://dx.doi.org/10.1016/j.ajodo.2008.07.008>

Corresponding Author

Dr. Preeti Bhardwaj
 Reader
 Department of Orthodontics and
 Dentofacial Orthopaedics,
 K.D. Dental College and Research Centre
 Mathura.
 Email: prety.dr@gmail.com
 Phone: +919411405205