

## CIRCUMMANDIBULAR WIRING IN PEDIATRIC MAXILLOFACIAL TRAUMA: A CASE REPORT.

<sup>1</sup> Shrutha S P  
<sup>2</sup>Vinit G B

<sup>1</sup> Senior Lecturer  
<sup>2</sup>Professor and Head

<sup>1</sup> Department of Pedodontics and Preventive Dentistry, Rama Dental College, Hospital and Research Centre.  
<sup>2</sup> Department of Oral and Maxillofacial surgery, Rama Dental College, Hospital & Research Centre, Kanpur.

### ABSTRACT:

Fractures in children are relatively uncommon due to high resiliency of bone. Mandibular fractures are most frequently fractured facial bone in pediatric patients after nasal bones. Construction of acrylic cap splints and retaining them over the fractured mandible with circummandibular wiring is ideal in such cases. Highly displaced fractures may require monocortical screws with plate fixation at inferior border of mandible to avoid damage to underlying teeth. One such case of displaced fractured mandible with circummandibular wiring and open reduction and internal fixation is presented here.

**KEYWORDS:** Mandibular fracture, Acrylic cap splint, Circummandibular wiring.

### INTRODUCTION

Mandibular fractures are most frequently fractured facial bone in pediatric patients after nasal bones<sup>1</sup>. There is an overall male predominance among children with facial fractures, reflecting the more aggressive and risk-taking behaviour of preteen and adolescent boys. Traffic accidents, falls and sports accident have been reported to be the most common causes of maxillofacial injuries<sup>2</sup>. In pediatric patients symphysis and parasymphysis fractures account for 15-20% and Body fractures are rare<sup>3</sup>.

Highly displaced fractures may require monocortical screws with plate fixation at inferior border of mandible to avoid damage to underlying teeth. The purpose of this article is to provide an insight on maxillofacial injuries in pediatric patient and its management in this unique and highly specialized area of traumatology.

### Case report:

A male patient aged eight years reported to the Department of Pedodontics and Preventive Dentistry, Rama Dental College, Hospital and Research centre, Kanpur (U.P.), with a history of fall from the 2<sup>nd</sup> floor of a building while playing. The patient was semi conscious and not well oriented when reported. History revealed no convulsions, vomiting or bleeding from ear and nose.

On Extra oral examination facial asymmetry due to oedema over the left side of face was noted. Deep

lacerated wound over the left lower border of the mandible with no evidence of active bleeding was found (Fig.1).

Intra oral examination revealed mixed dentition with highly displaced fracture at the left parasymphysis region. The occlusion was profoundly deranged and patient was unable to close his mouth (Fig.2). Postero anterior view [PA view] revealed highly displaced fracture in left parasymphysis region of the mandible (Fig.3).

Treatment was planned in concurrence with Department of Oral and Maxillofacial surgery. Under local anesthesia, the mandibular arch was reduced manually to achieve normal occlusion and stabilized temporarily with figure of '8' wiring (Fig.4). Impression made and acrylic cap splint fabricated over the cast (Fig.5). The patient was then shifted to the Operation Theatre and General Anesthesia administered. Circummandibular wiring was performed to stabilize the splint intraorally to retain the normal occlusion (Fig.6). The external lacerated wound over the left lower border of mandible was thoroughly debrided and through the same route fractured mandible was exposed, reduced and fixed using a titanium miniplate and screws. The wound was then closed in layers. Postoperative OPG was taken to visualise the reduced fractured fragments and the position of miniplate in relation to the tooth buds (Fig.7). Patient was recalled for review periodically. The acrylic splint was retained for three weeks and the circummandibular wiring was subsequently removed following which the desired result was achieved.

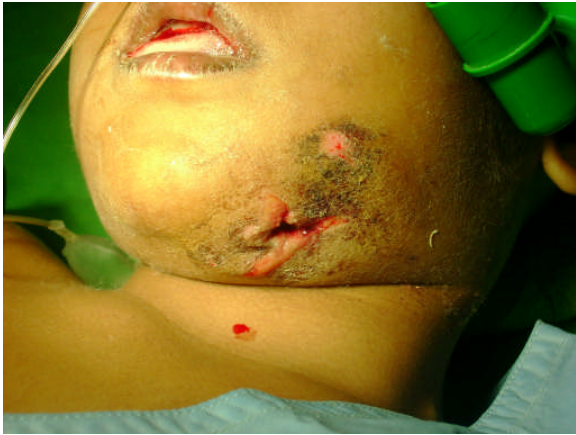

Fig.1. Preoperative extraoral lacerated wound

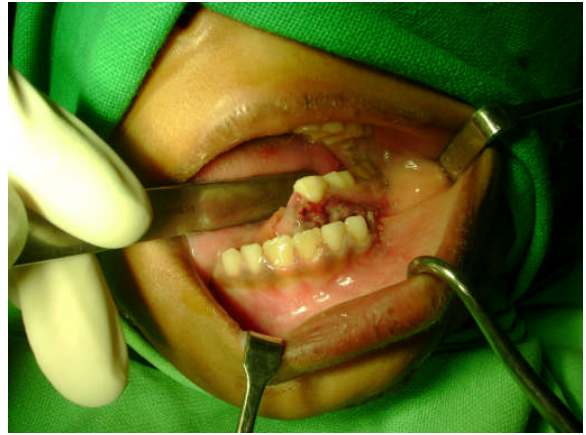


Fig.2. Displaced fracture of left side mandible

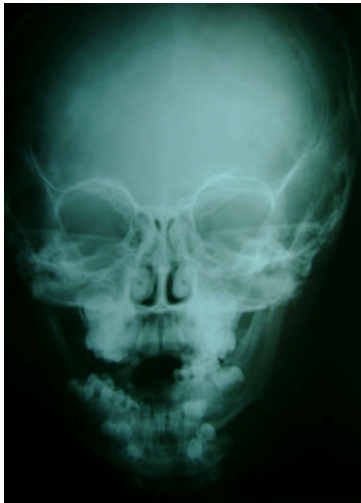


Fig.3. Preoperative PA View radiograph

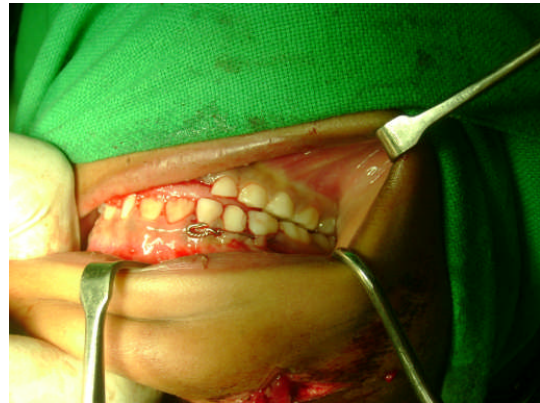

Fig.4 . Reduced mandible fracture and teeth in occlusion

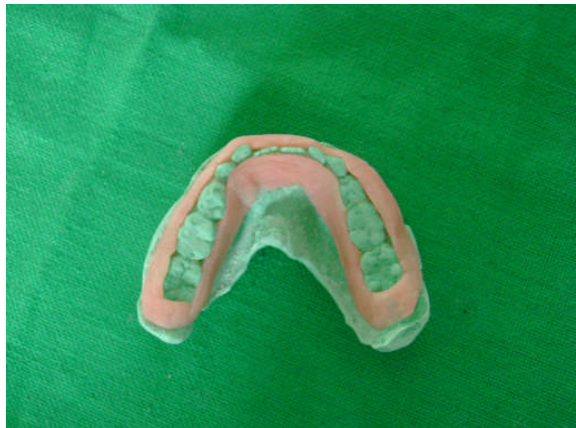

Fig.5 . Fabricated Acrylic cap splint in the mandible model

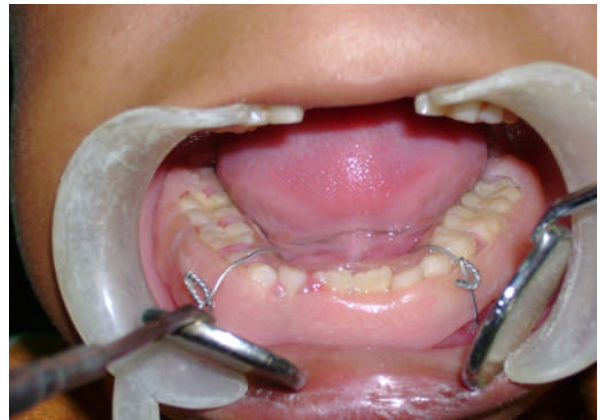

Fig.6. Circummandibular wiring done and final placement of cap splint in the mandible.

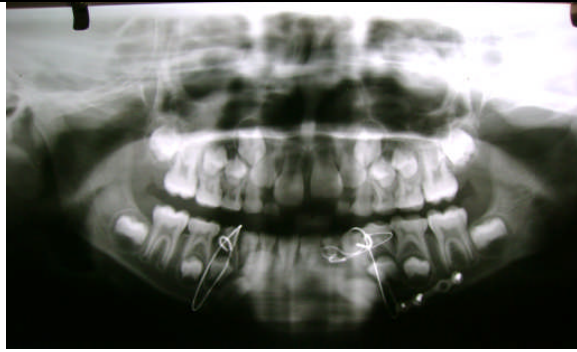


Fig.7 – Postoperative OPG radiograph

### Discussion

The management of the paediatric patient with maxillofacial injury should take into consideration the differences in anatomy and physiology between children and adults, the presence of concomitant injury, the particular stage in growth and development (anatomic, physiologic, and psychological), and the specific injuries and anatomic sites that the injuries affect<sup>2</sup>.

In European and American countries the use of mini-plate osteosynthesis has become increasingly popular for the management of mandibular fracture<sup>3</sup>. Displaced fractures usually require open reduction with or without internal fixation by plating. The treatment of mandibular fractures in children is different from that in adults because of the presence of deciduous and unerupted teeth. For parasymphiseal and body fractures, stabilization can also be achieved using acrylic splints. These splints are fashioned from dental impressions. In the case of displaced fractures, the models are cut at the fracture site and are repositioned to establish the preinjury occlusion. A splint is then made of acrylic to fit the mandibular dentition. The splint is then secured in position with circummandibular wires<sup>4</sup>.

In the present case, since the fracture was highly displaced with gross derangement of occlusion, it was decided to opt for open reduction and internal fixation through the existing laceration. Desired occlusion was retained with an acrylic cap splint that was stabilized by circummandibular wiring.

### CONCLUSION

In conclusion facial trauma in children can often be challenging to manage with long-term consequences involved. Maxillo-facial injuries may be quite dramatic causing parents to panic and the child to cry uncontrollably with blood, tooth and soft tissue debris in the mouth. The facial disfigurement caused by trauma can have a deep

psychological impact on the tender minds of young children and their parents.

The pure joy and satisfaction derived after treating such children is unparalleled.

### References

1. Das UM, Nagarathna C, Viswanath D, Keerthi R and Gadicherla P. Management of facial trauma in children: A case report. J Indian Soc Pedod Prev Dent - September 2006;157 -60.
2. Cavalcanti AL and Melo TR. Facial and oral injuries Brazilian children aged 5-17 years: 5-year review. European Archives of Paediatric Dentistry, June, 2008.
3. Bataineh AB. Etiology and incidence of maxillofacial fractures in the north of Jordan. Oral Surg Oral Med Oral Pathol Oral Radiol Endod 1998; 86:31-35. [http://dx.doi.org/10.1016/S1079-2104\(98\)90146-9](http://dx.doi.org/10.1016/S1079-2104(98)90146-9)
4. James F Thornton MD and Larry H Hollier MD. Facial Fractures II : Lower Third, SRPS Volume 9, no. 27, pp 24-6.
5. Posnick JC, Wells M, Pron GE. Pediatric facial fractures: evolving patterns of treatment. J Oral Maxillofacial Surg 1993; 51: 836-44. [http://dx.doi.org/10.1016/S0278-2391\(10\)80098-9](http://dx.doi.org/10.1016/S0278-2391(10)80098-9)
6. Kaban LB. Diagnosis and treatment of fractures of facial bones in children. J Oral Maxillofac Surg 1993;51:722-29. [http://dx.doi.org/10.1016/S0278-2391\(10\)80409-4](http://dx.doi.org/10.1016/S0278-2391(10)80409-4)
7. Haugrh, Foss J. Maxillofacial injuries in the pediatric patient. Oral Surg Oral Med Oral Pathol Oral Radiol Endod 2000;90;126-34. <http://dx.doi.org/10.1067/moe.2000.107974> PMID: 10936829
8. James D. Maxillofacial injuries in children. In: Rowe NL, Williams JL, editors. Maxillofacial Injuries. Churchill Livingstone: p. 538-58.

### Corresponding Author

#### Dr. Shrutha S.P

Flat no 307, Staff Accomadation  
Rama Dental College Campus, A/1-8  
Lakhanpur,  
Kanpur(U.P), India.  
Phone No. 9935663392  
e-mail: shruthavinit@gmail.com